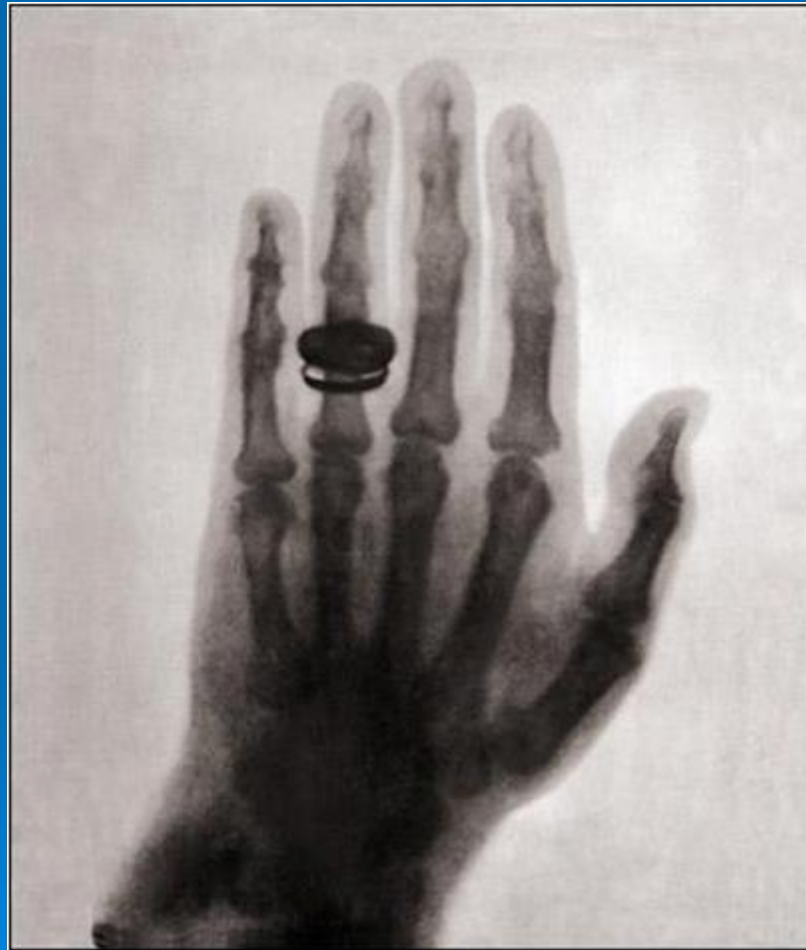

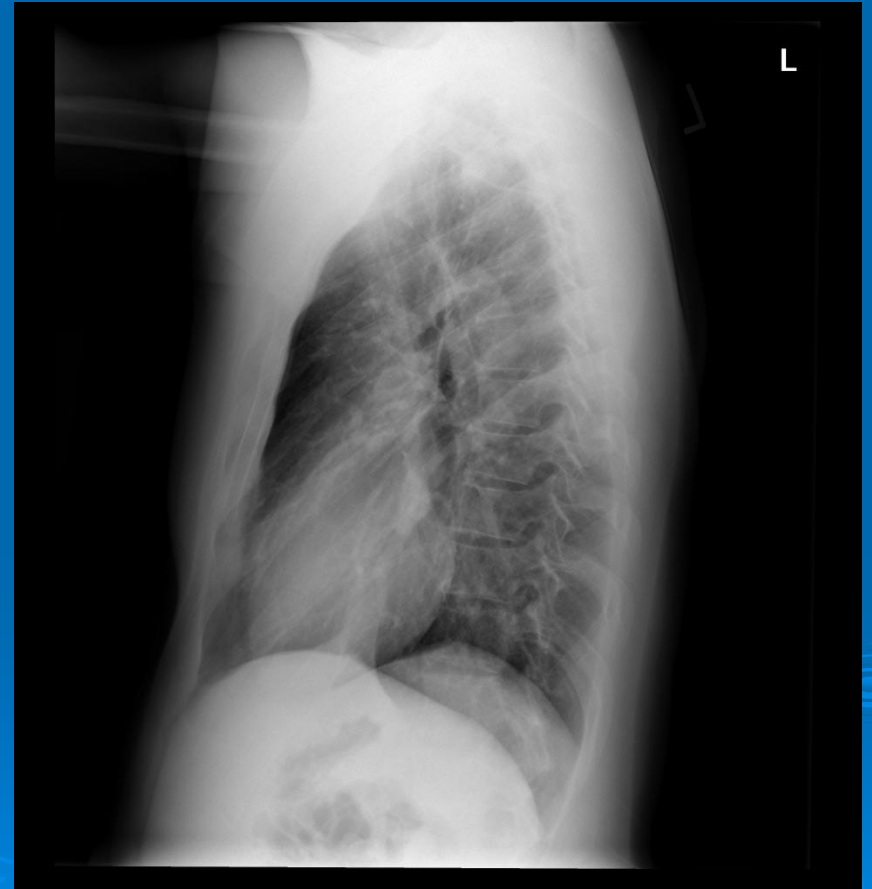
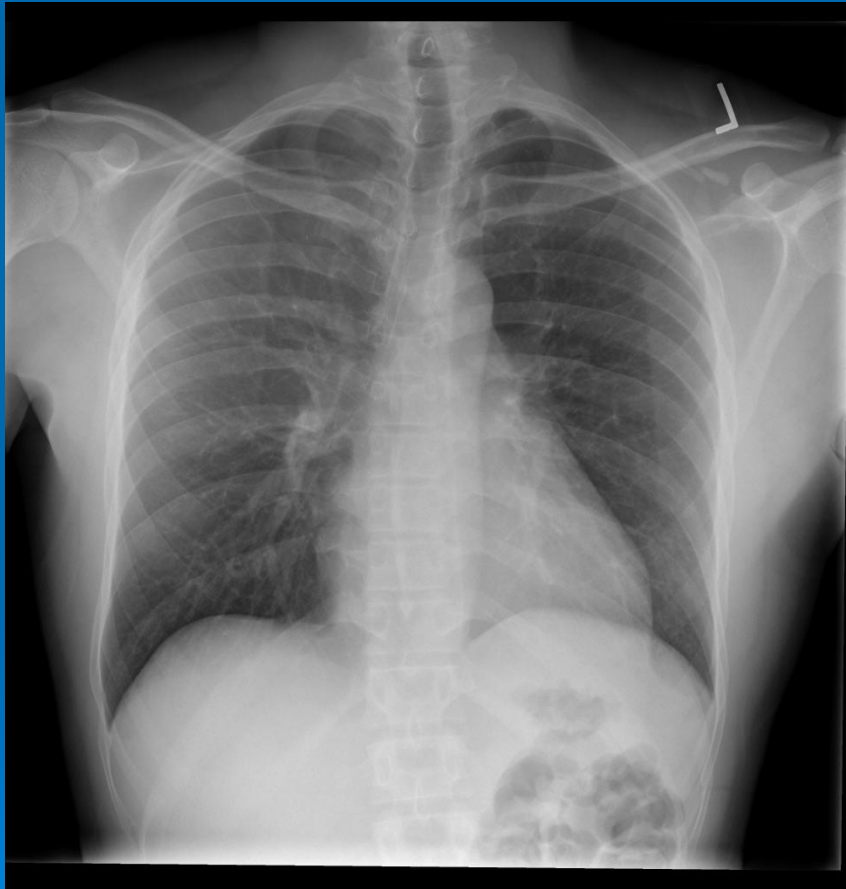
Introduction to thoracic imaging



Anna Bertha



33y/o with chest pain



What can go wrong (categories)?

congenital/developmental

metabolic/nutritional

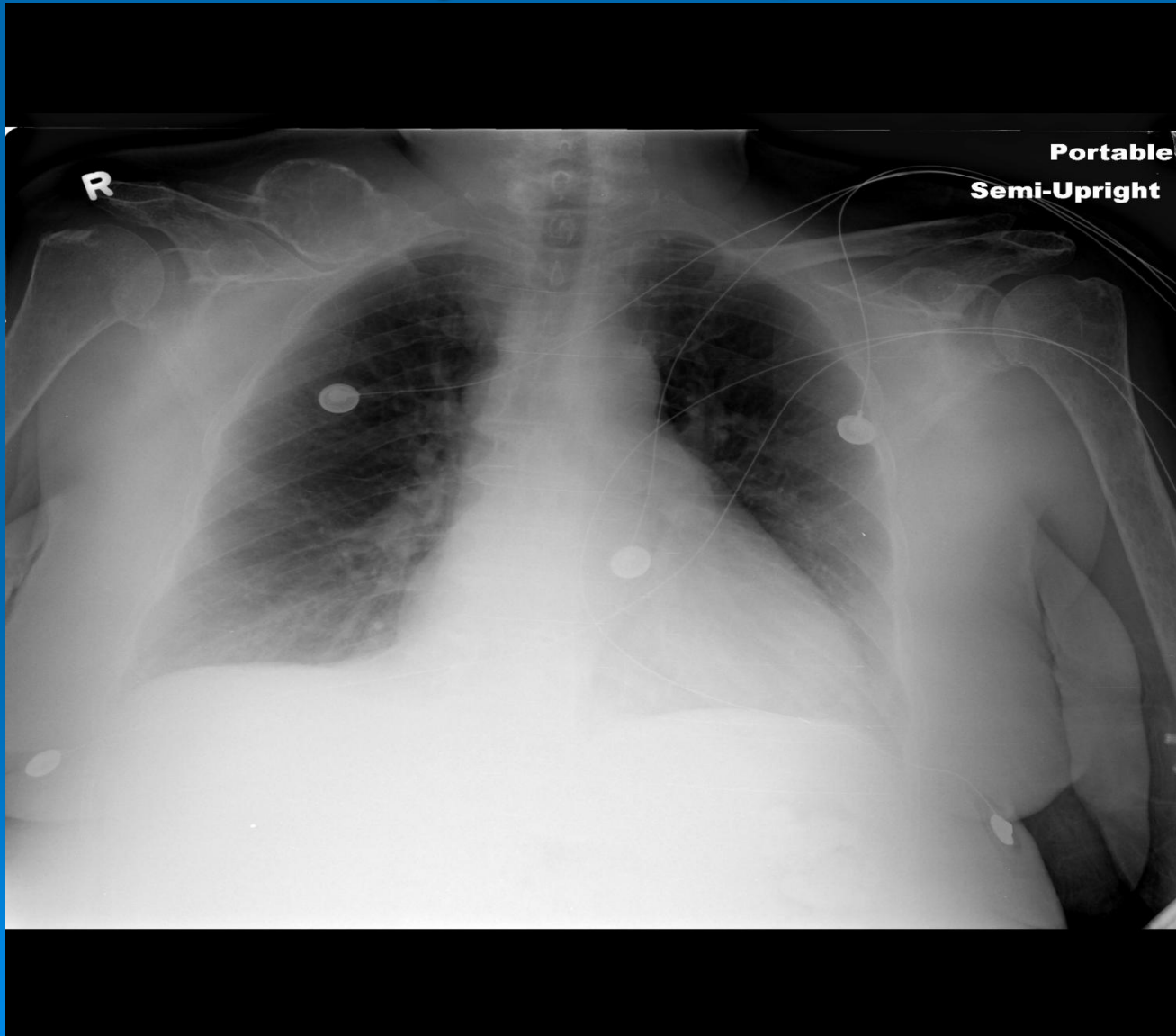
traumatic/degenerative

infectious/inflammatory/infiltrative

vascular/autoimmune

neoplastic

67 y/o c/o pain



Always ask:

What's wrong?

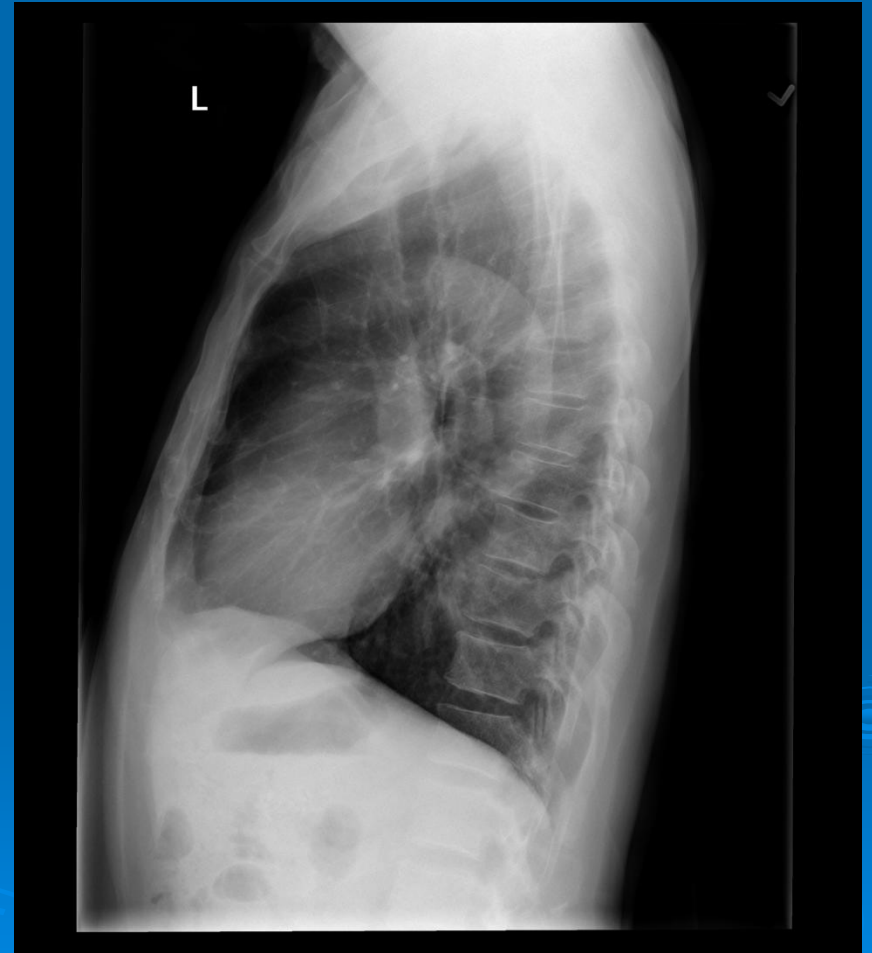
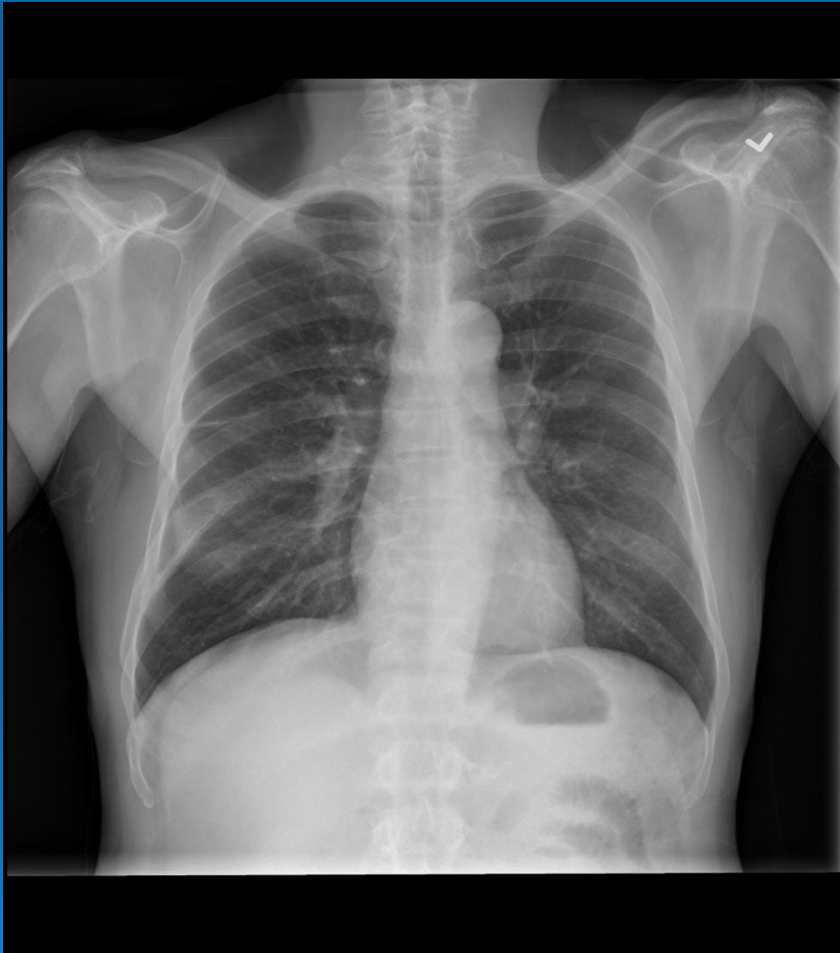
What is it?

What else could it be?

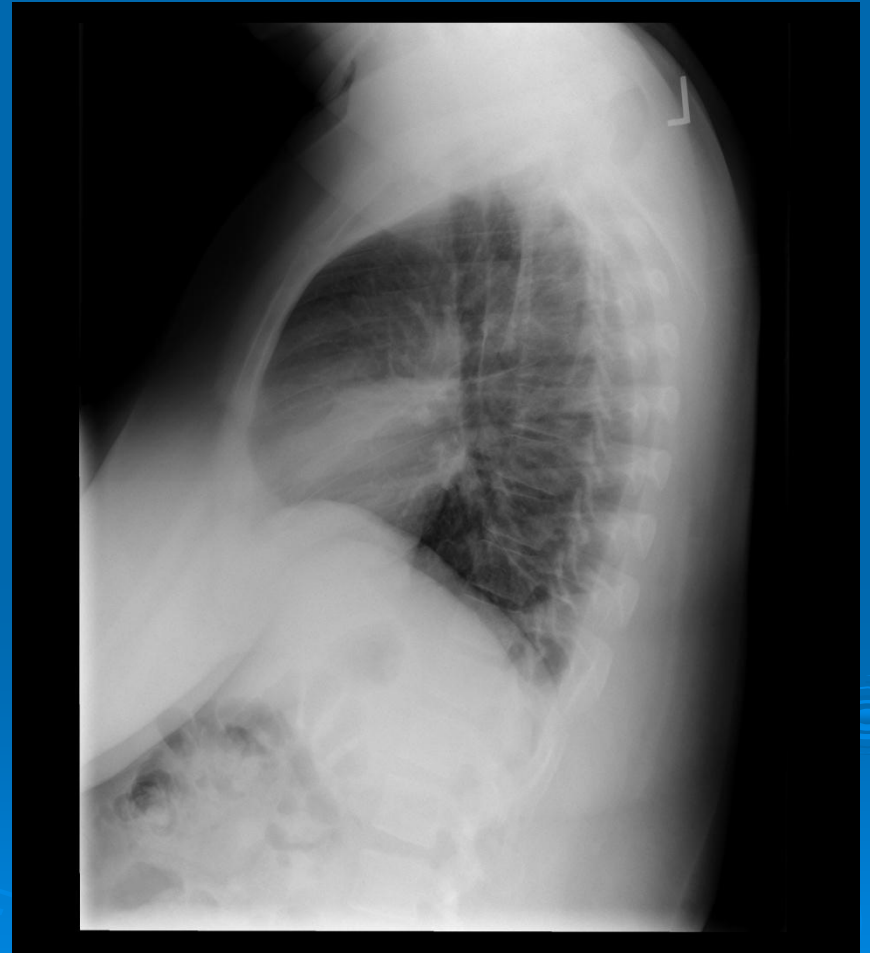
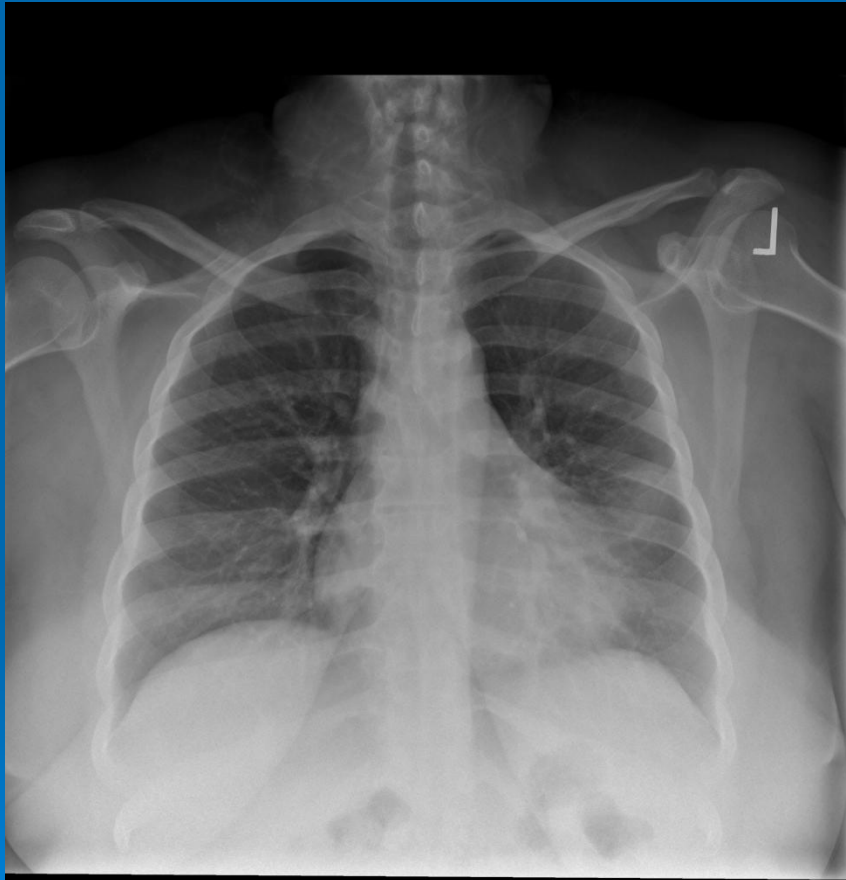
What else is wrong?




61 y/o; “pre-op”

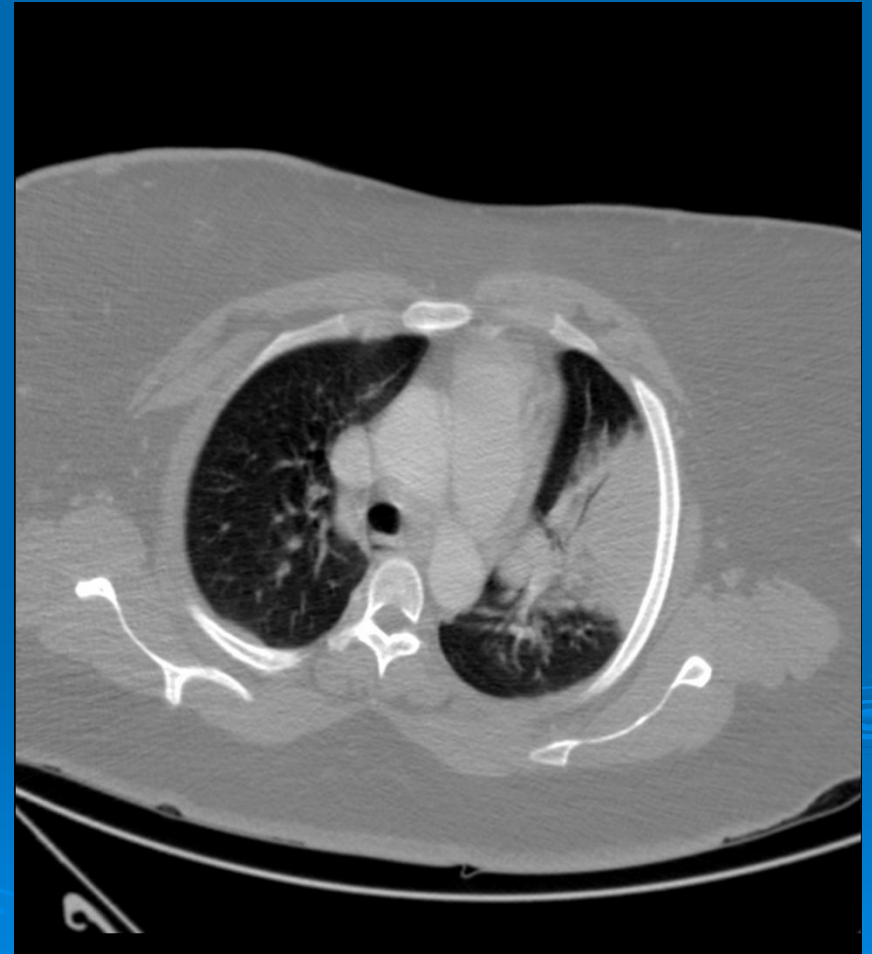
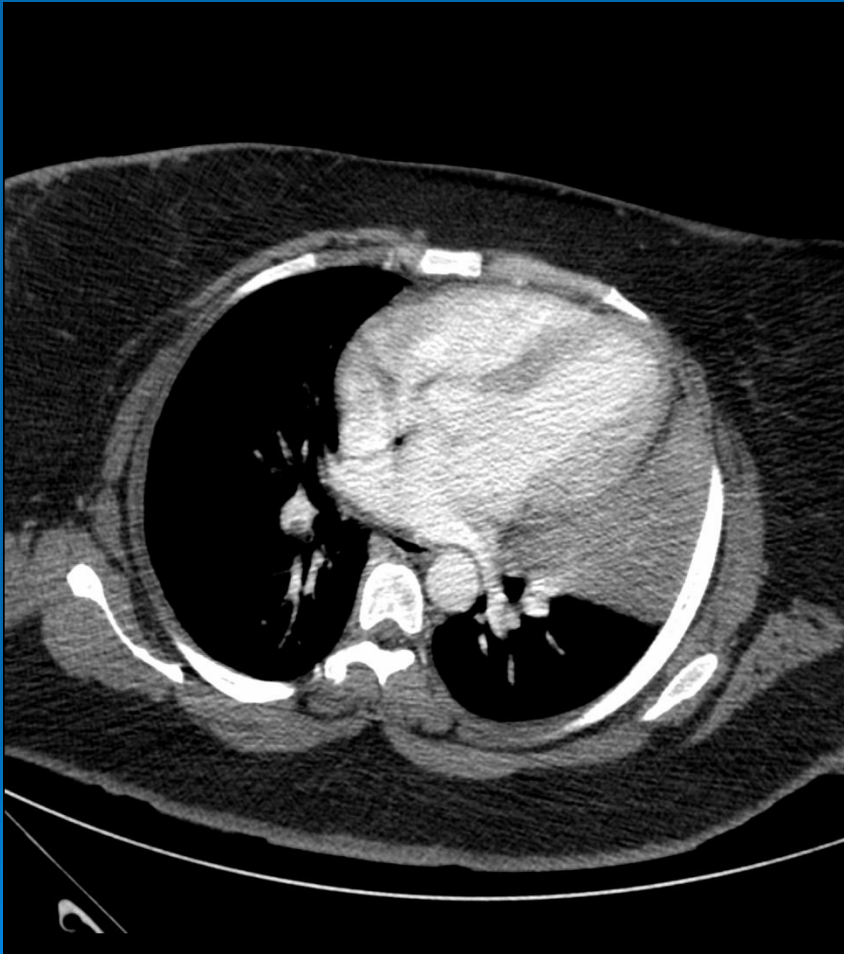


28 y/o c/o R chest pain





Fleas & tics, too



Remember:

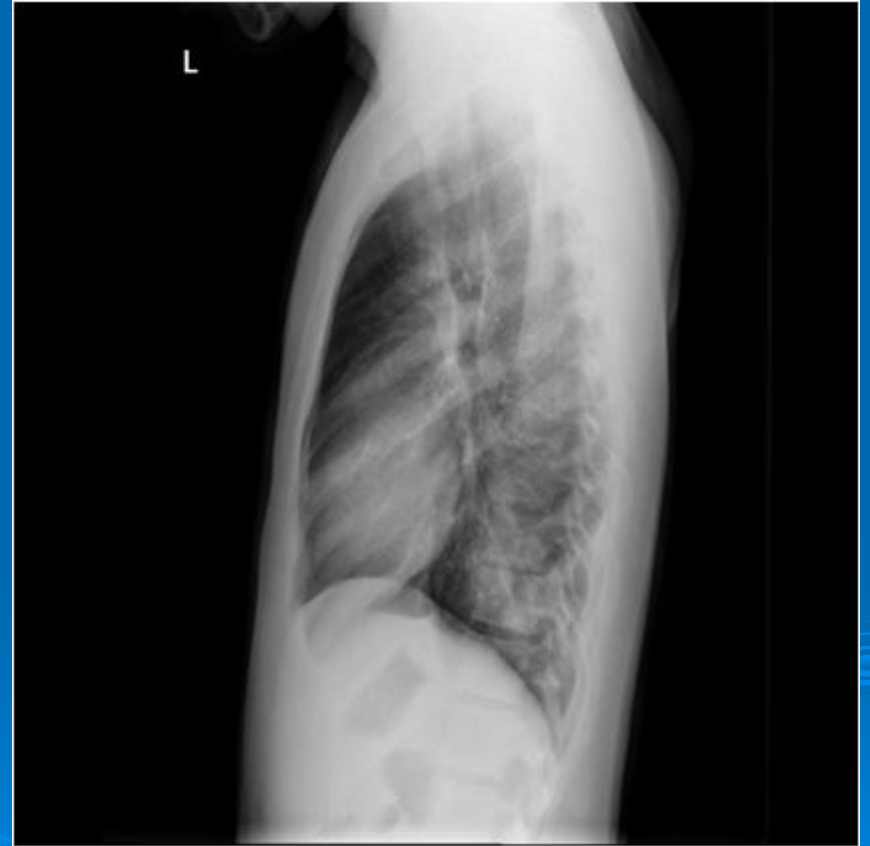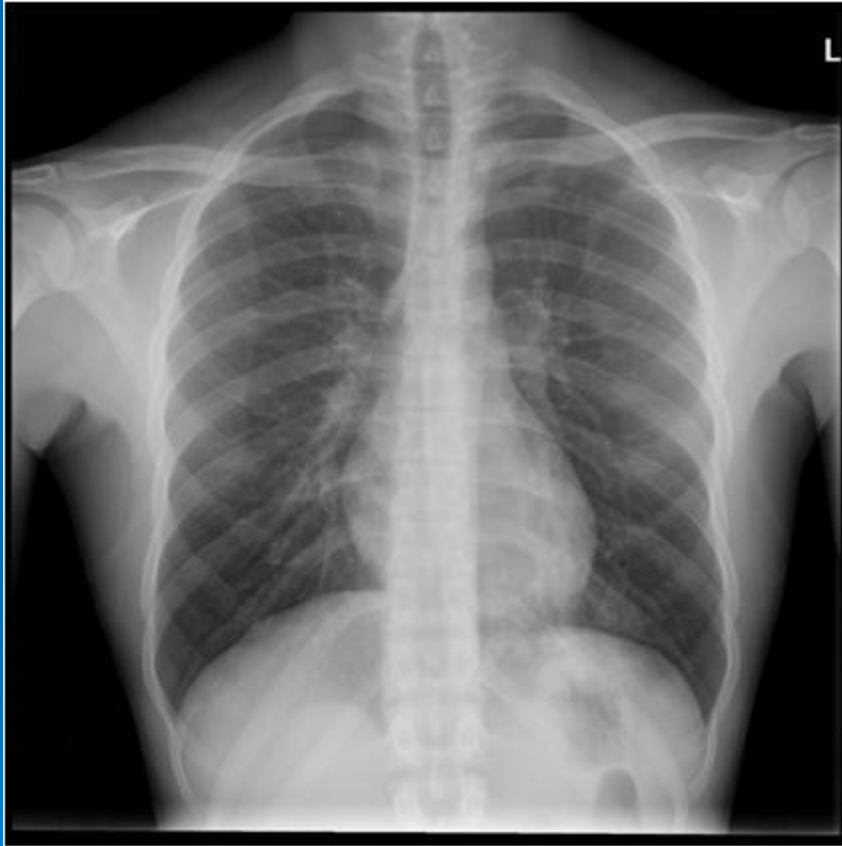
Silhouette sign

Air bronchogram

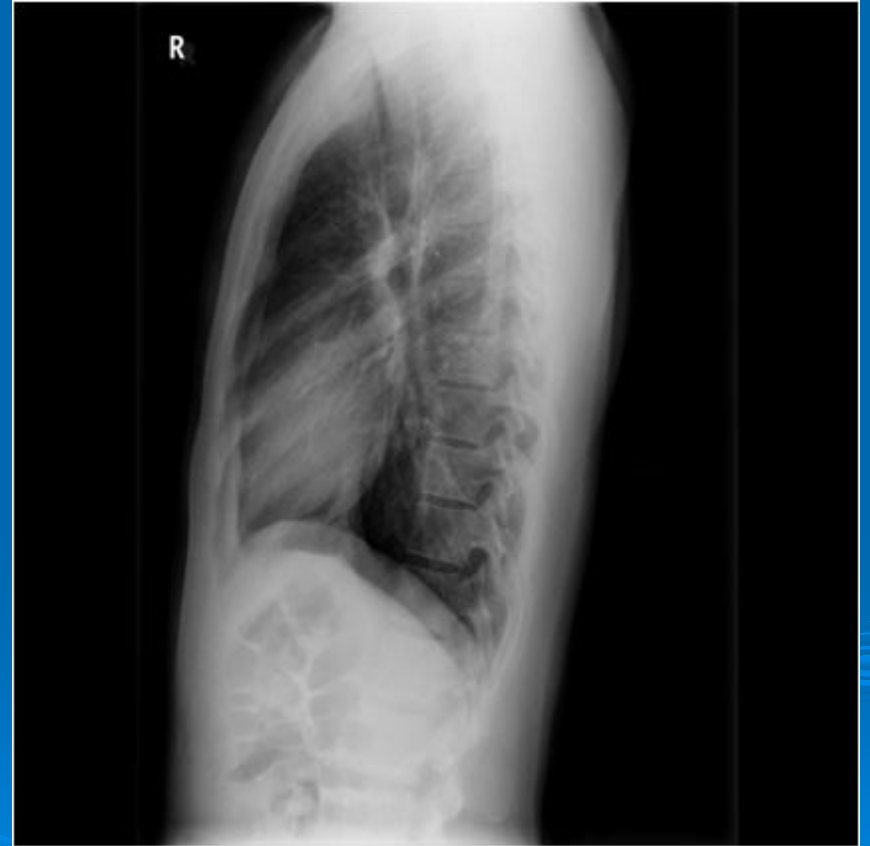
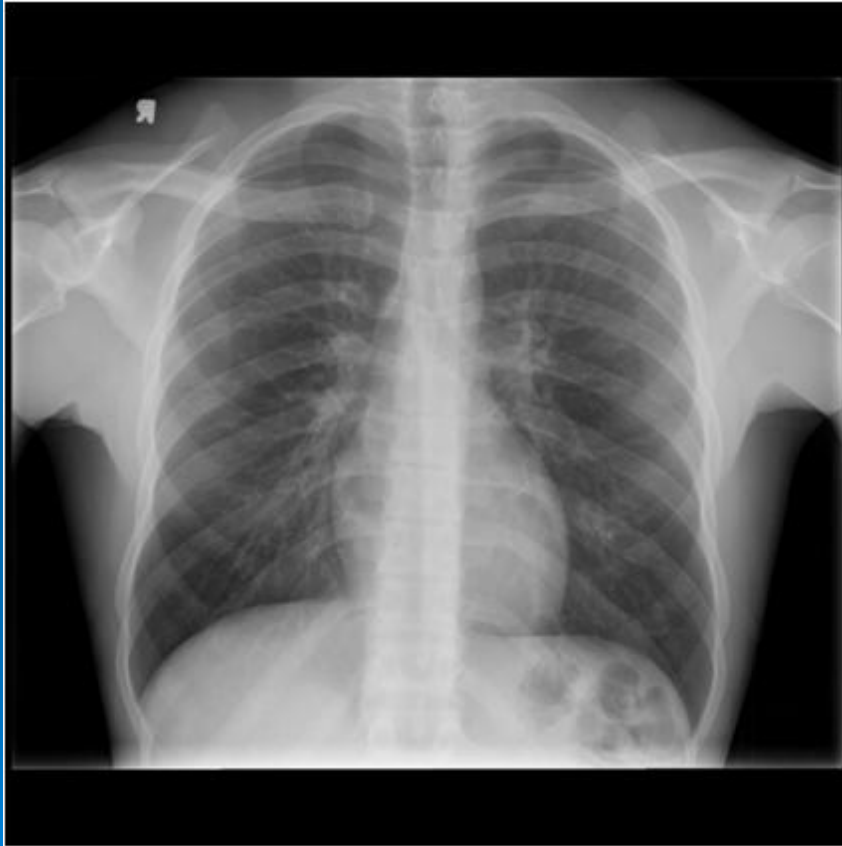
Airspace disease (preferred over “infiltrate”)



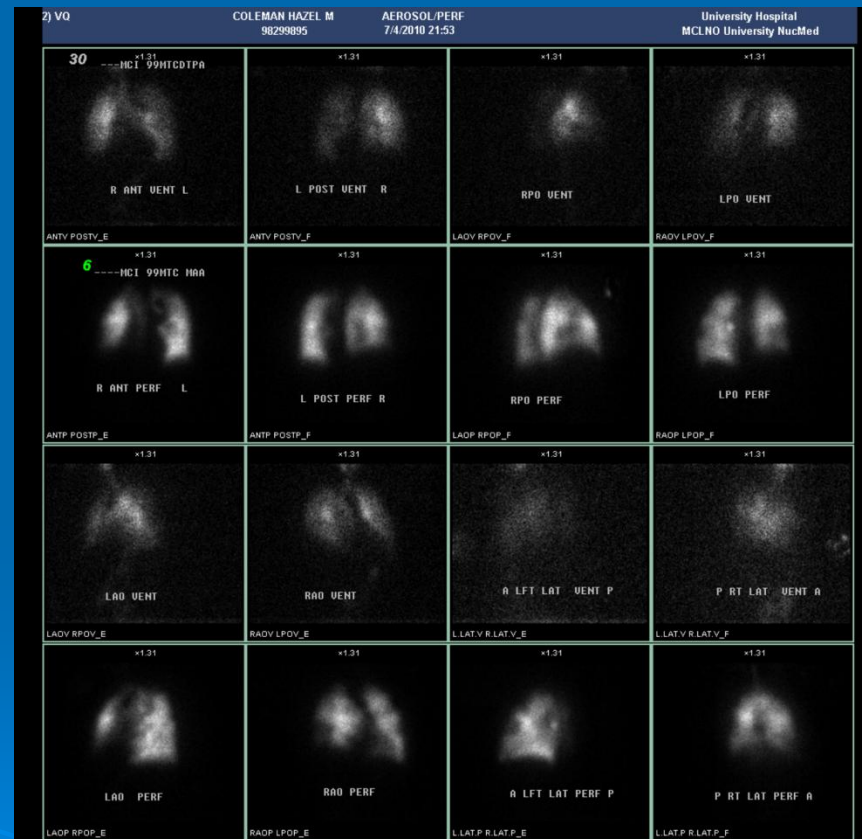
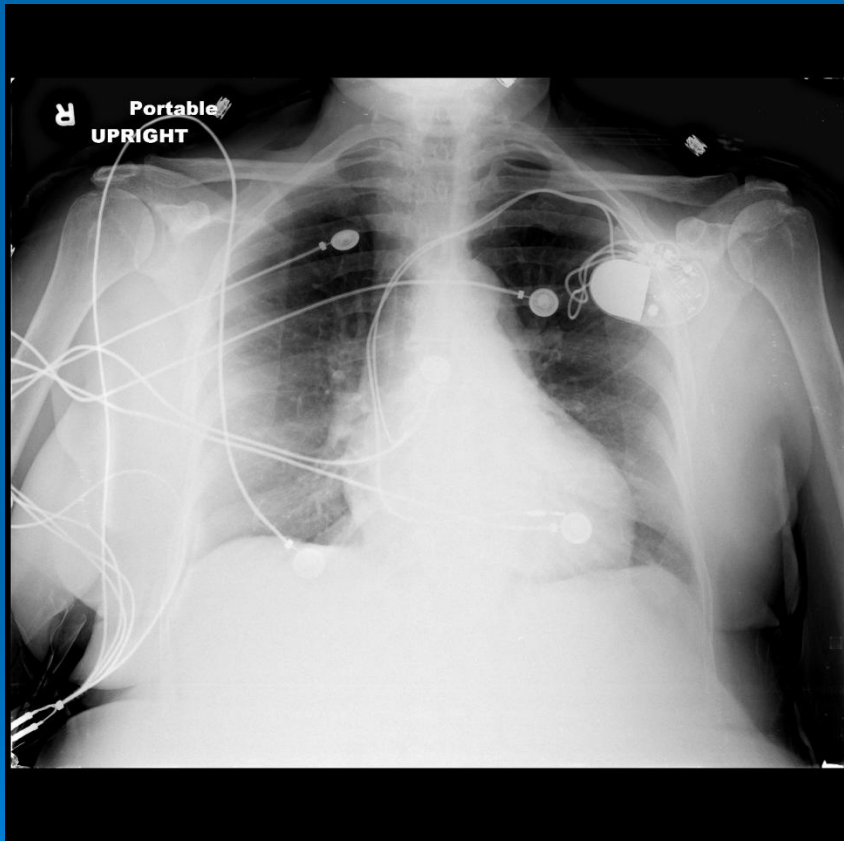
24 y/o with cough, fever



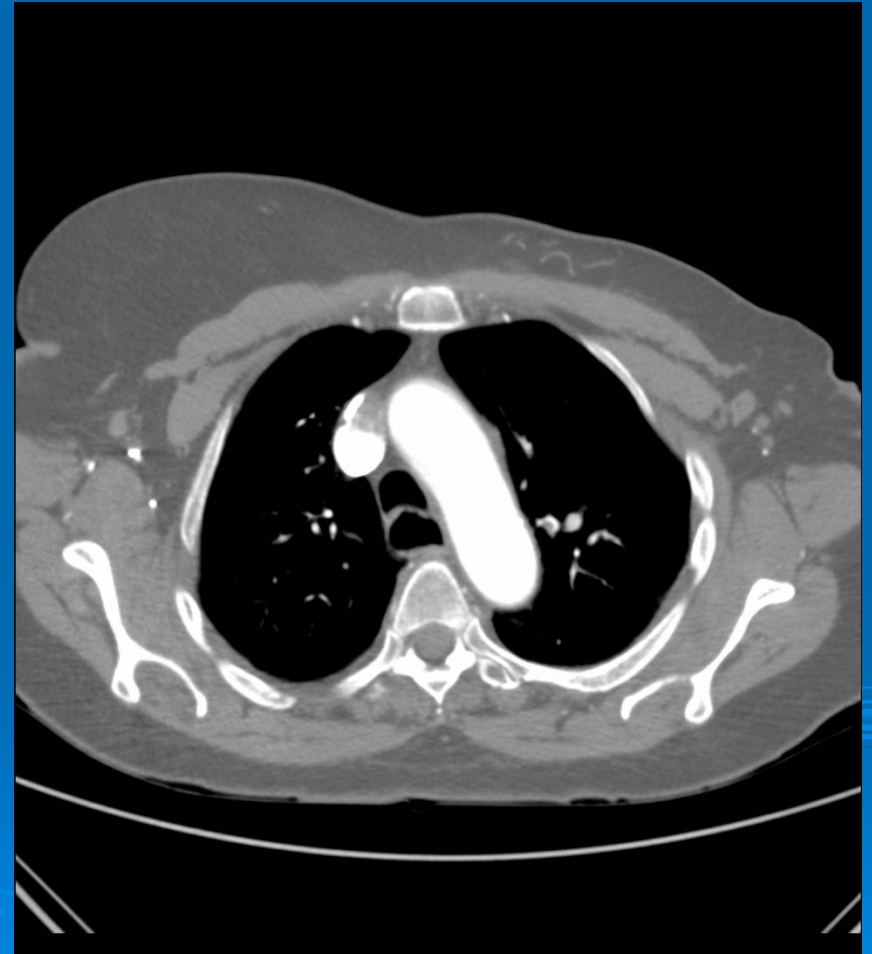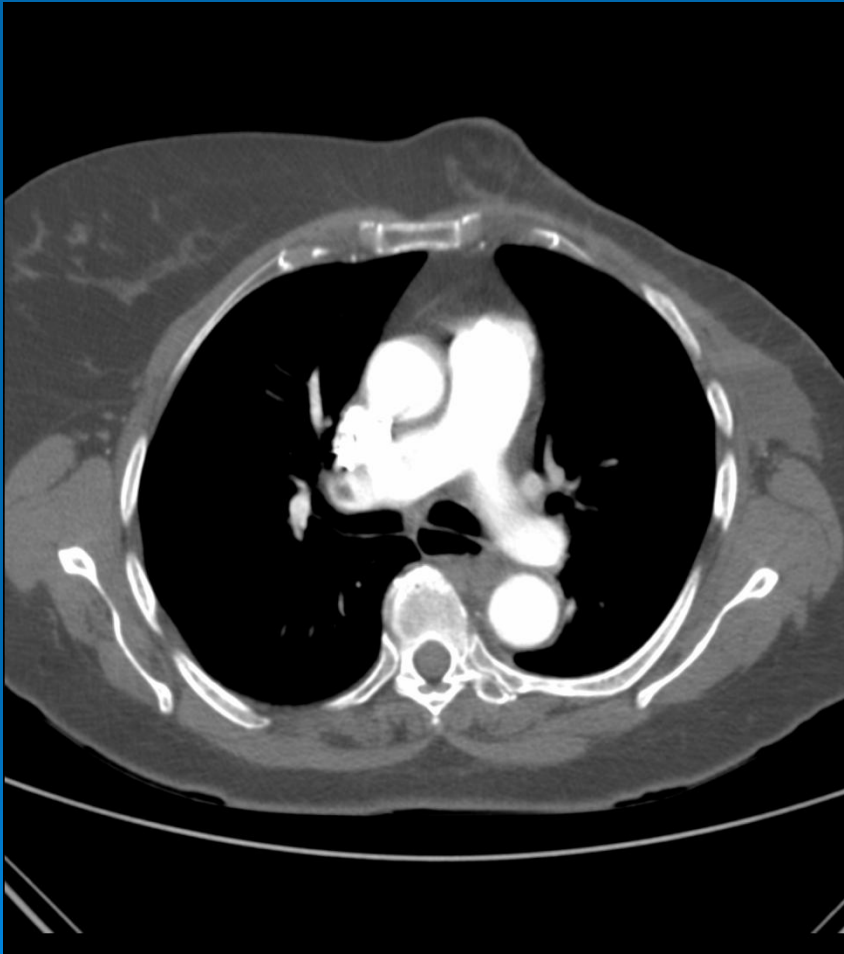
* “spine sign”



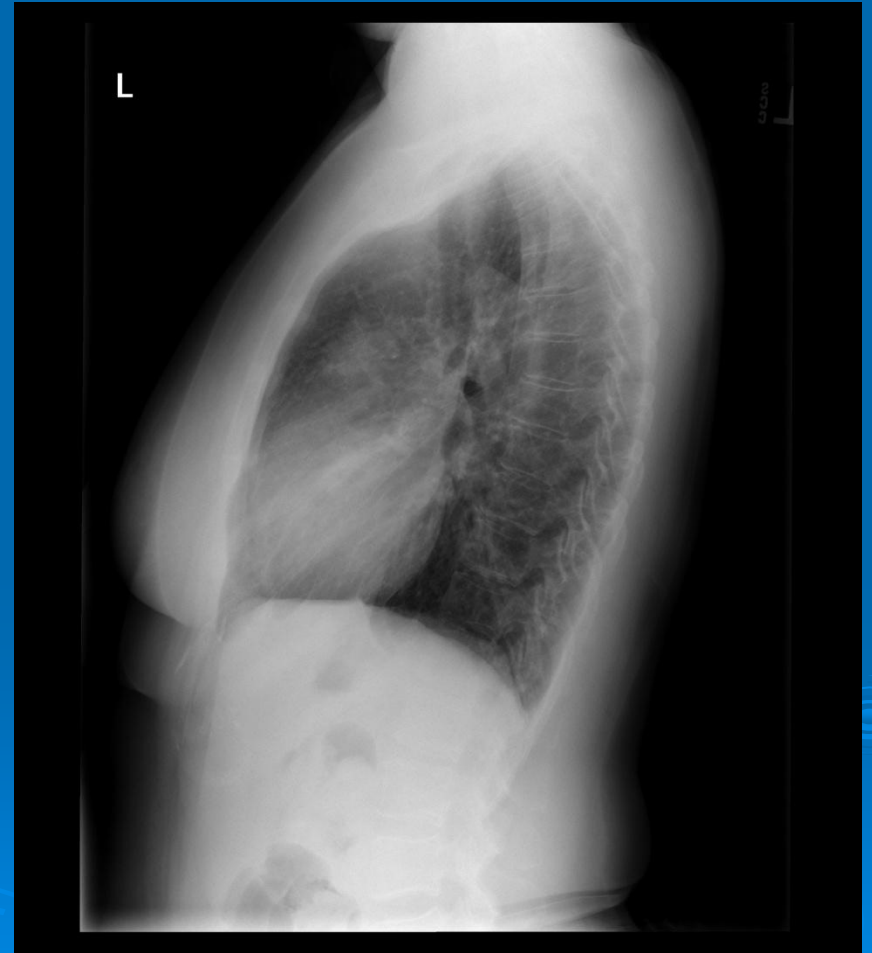
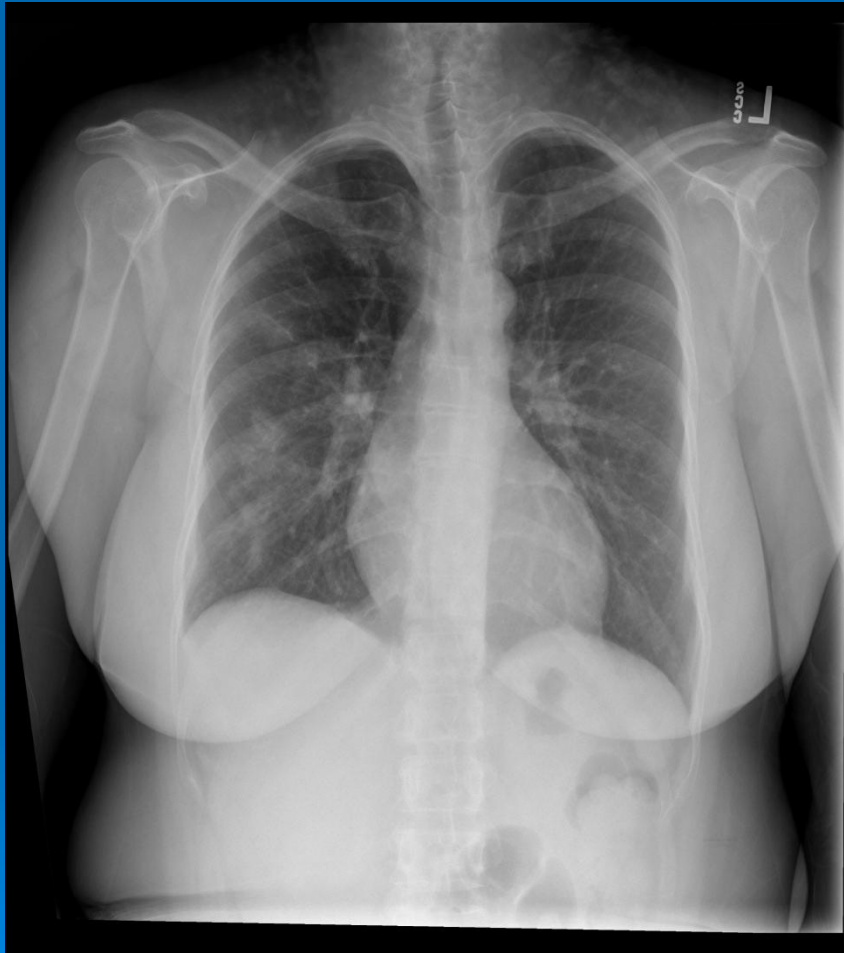79 y/o c/o CP, SOB



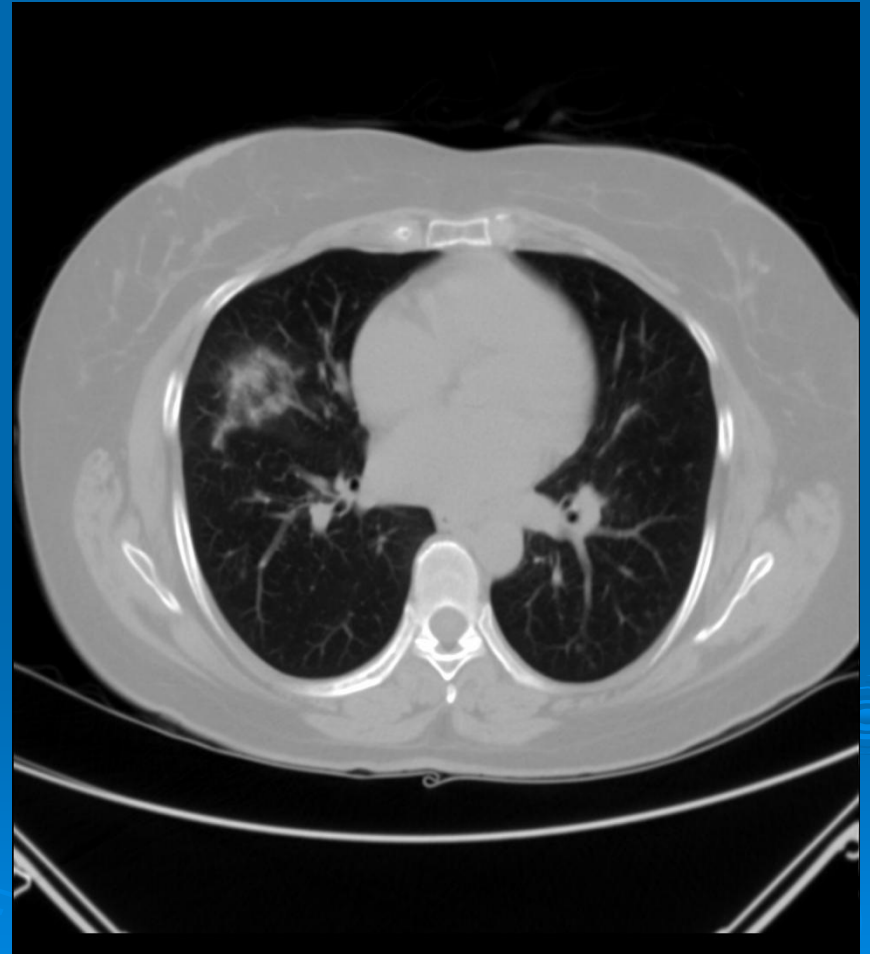
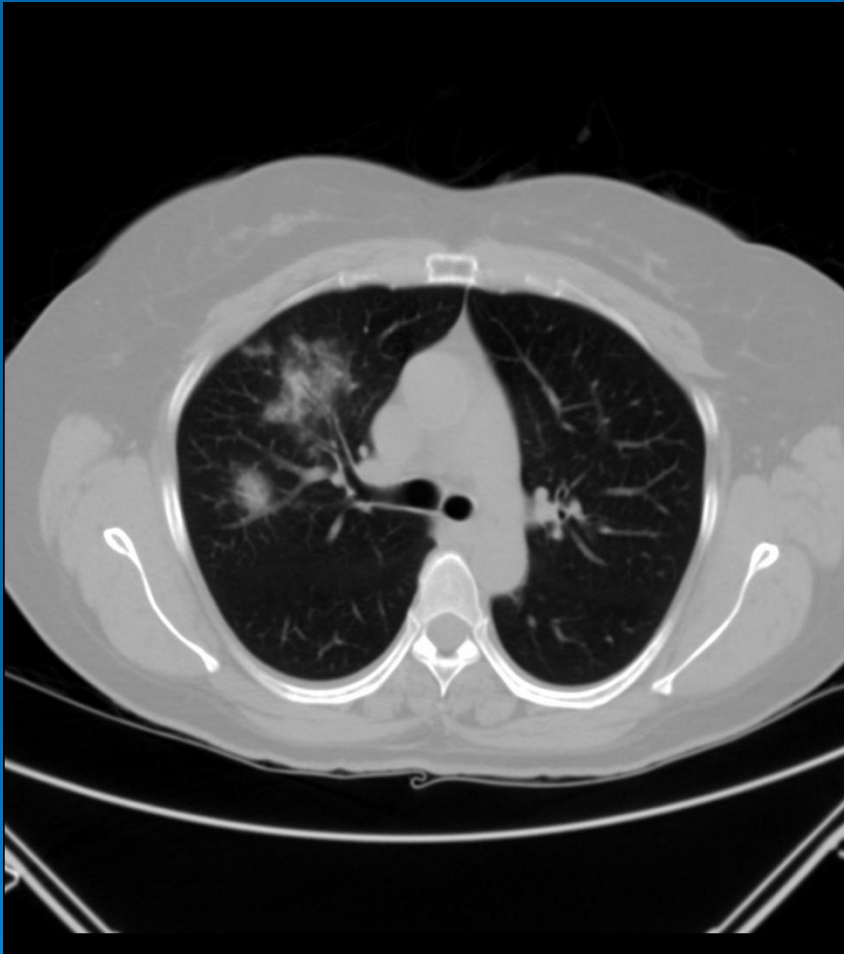Petmd



56 y/o with cough



Patchy, peri-bronchial



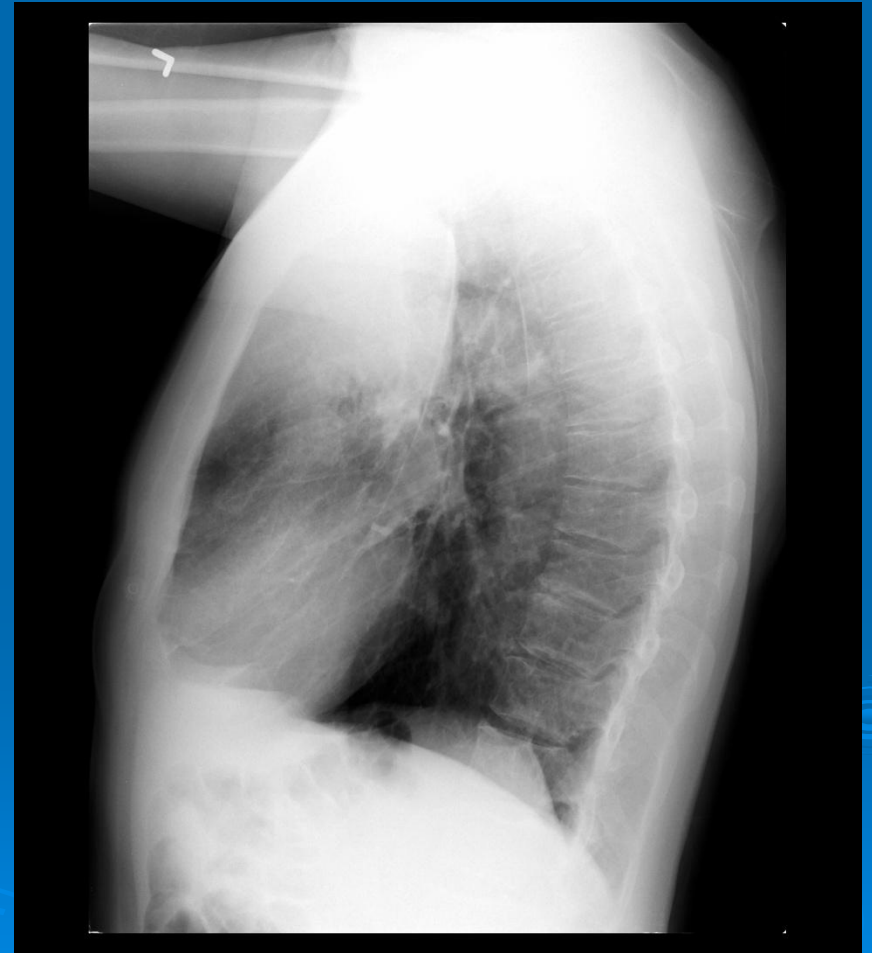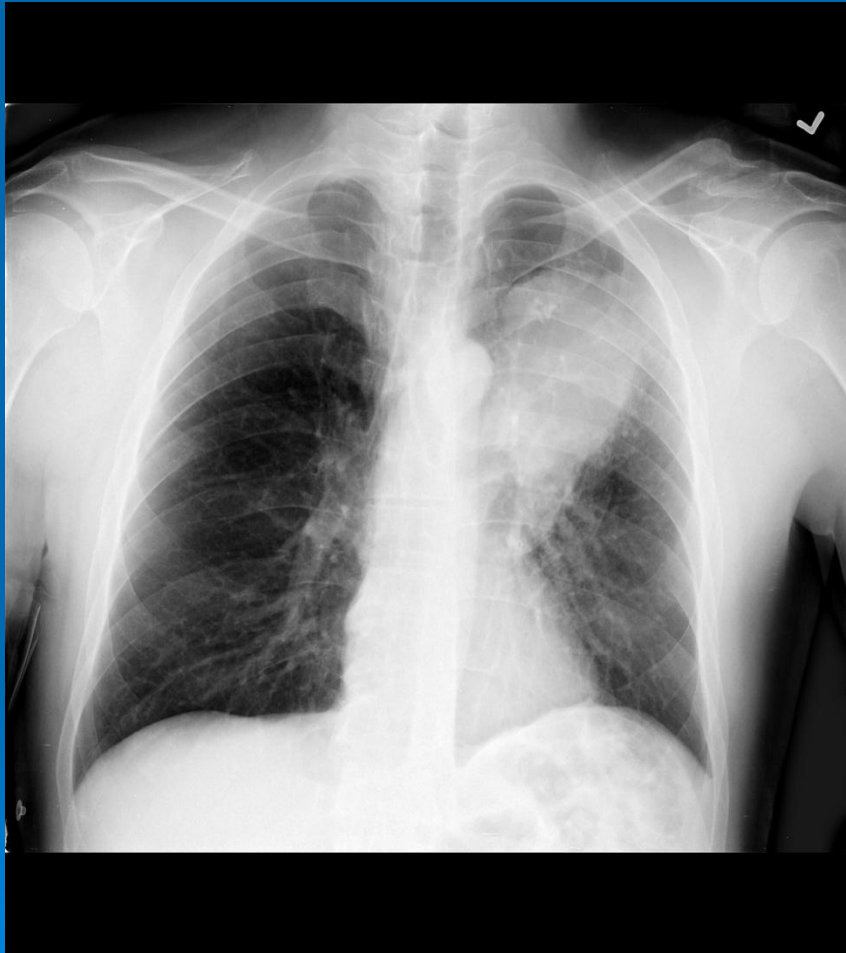Remember:

Acinar (preferred over alveolar)

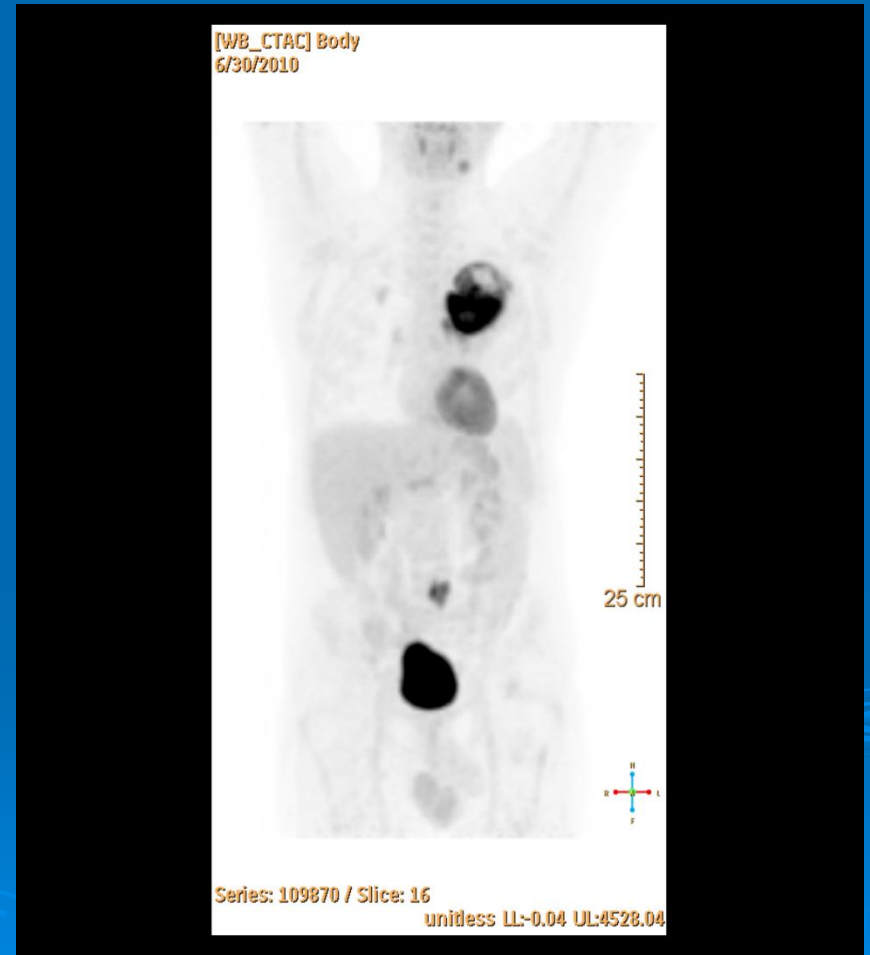
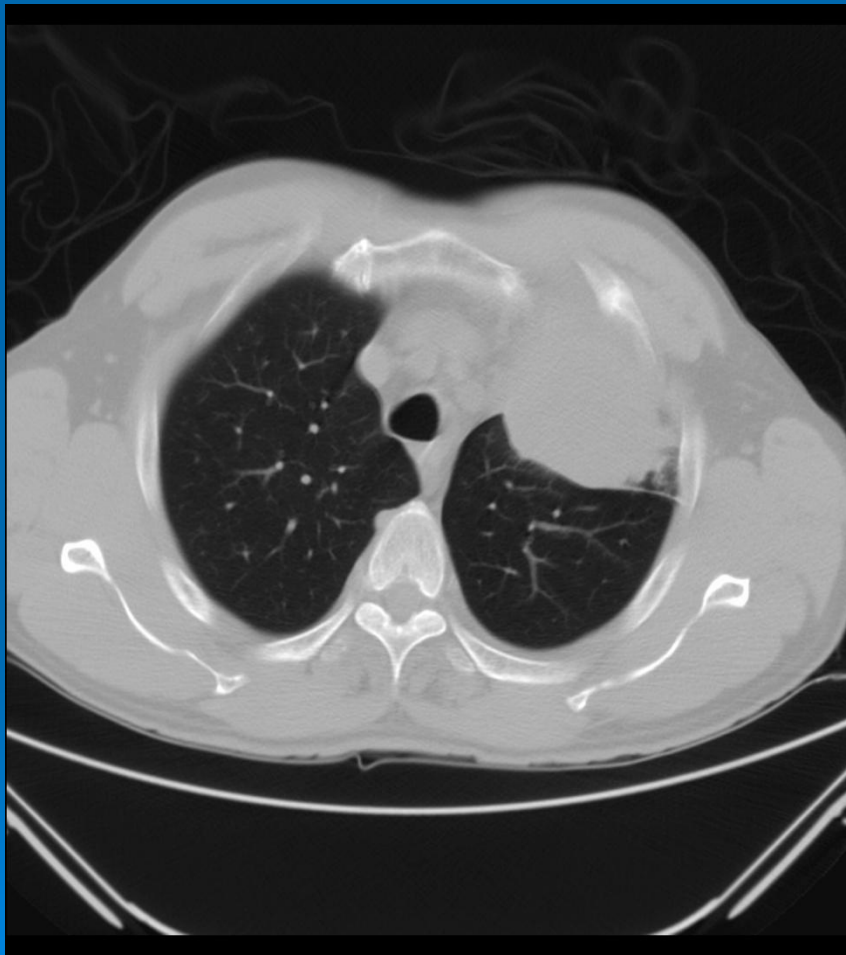Boyden's classification (lobar anatomy)



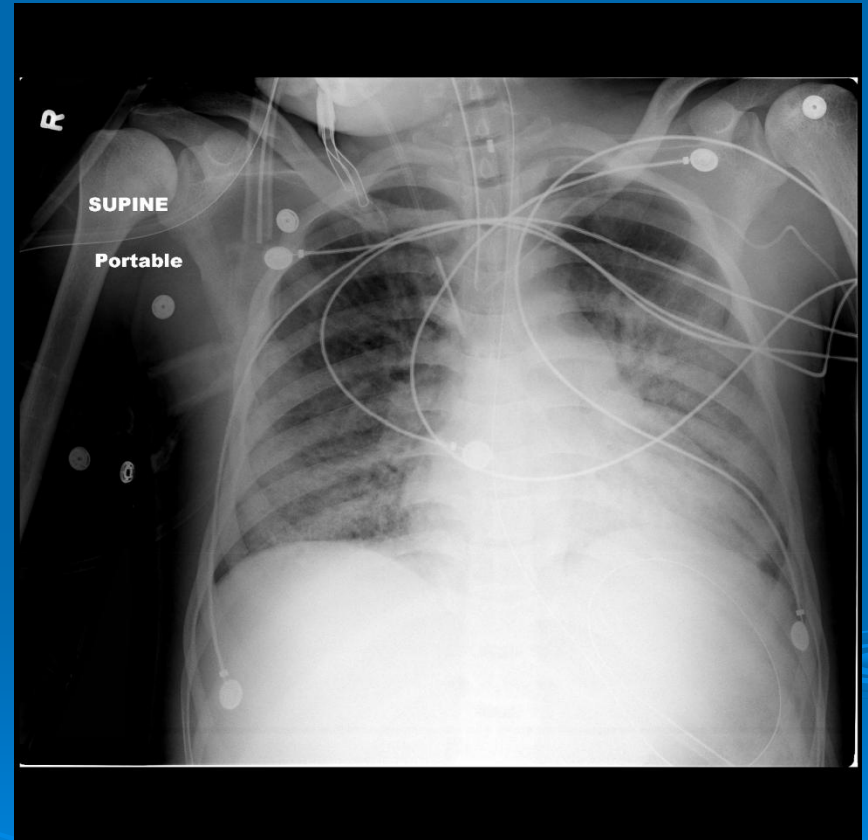
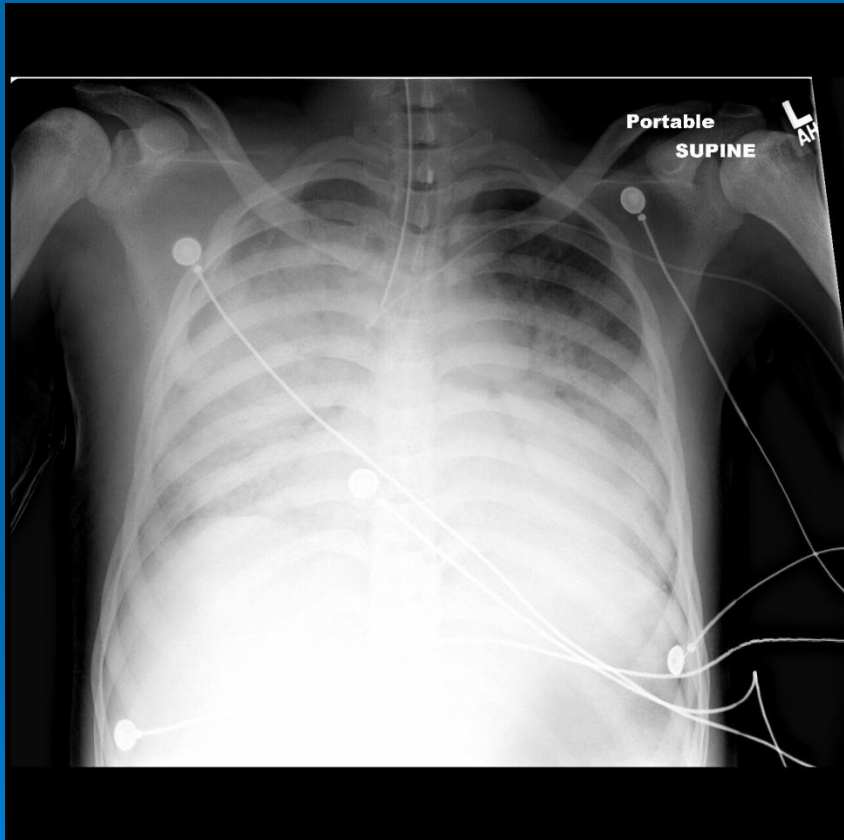
54 y/o c/o cough



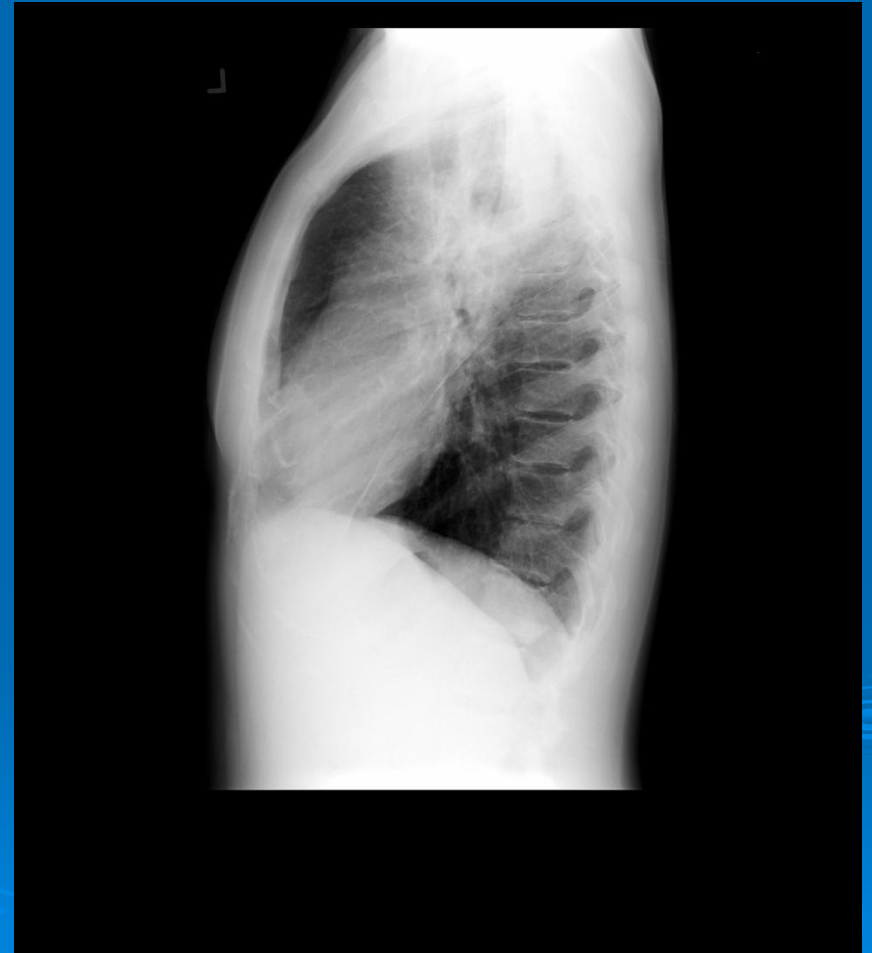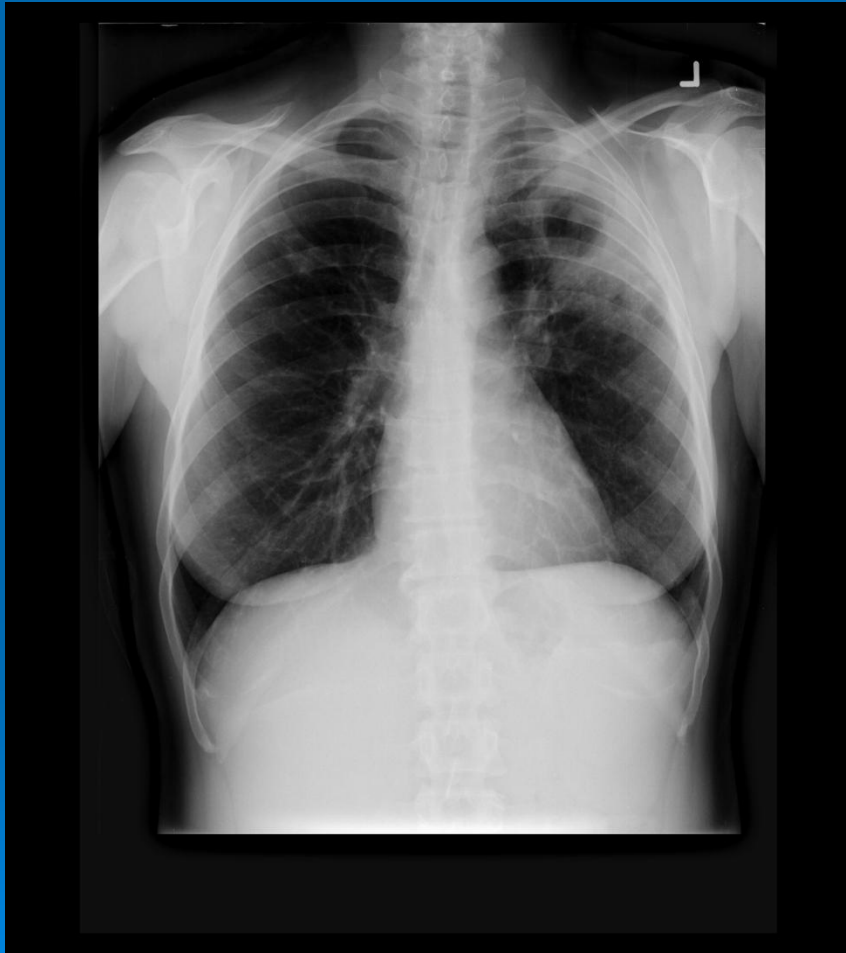
Mass & LUL atelectasis



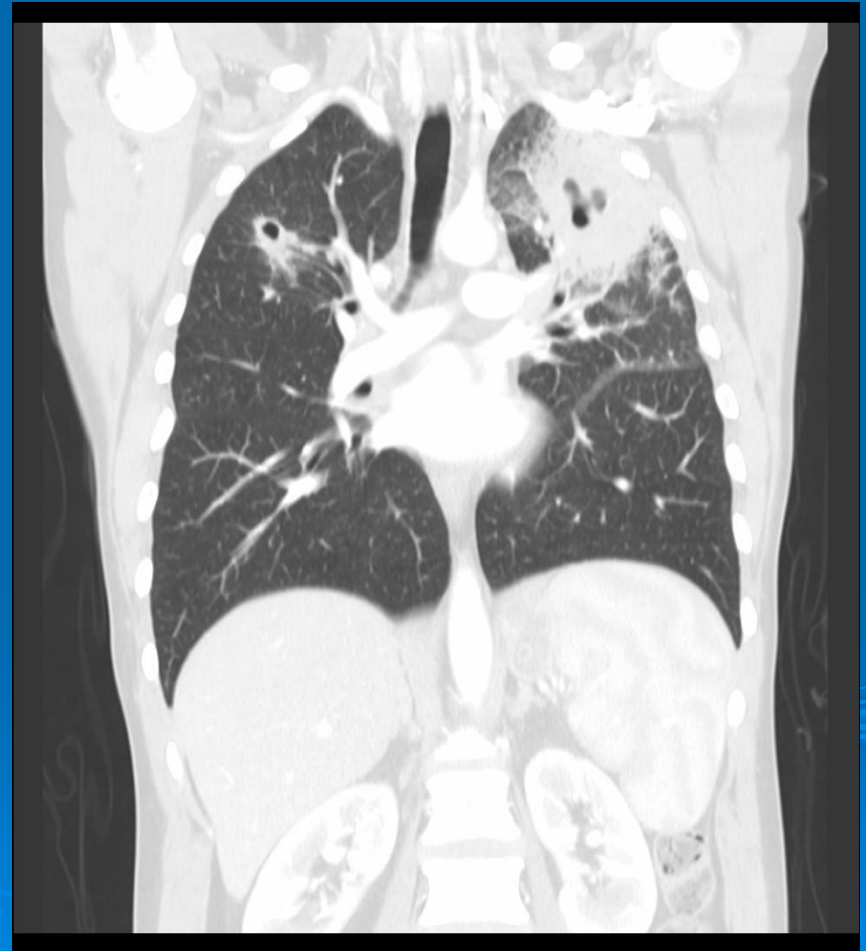
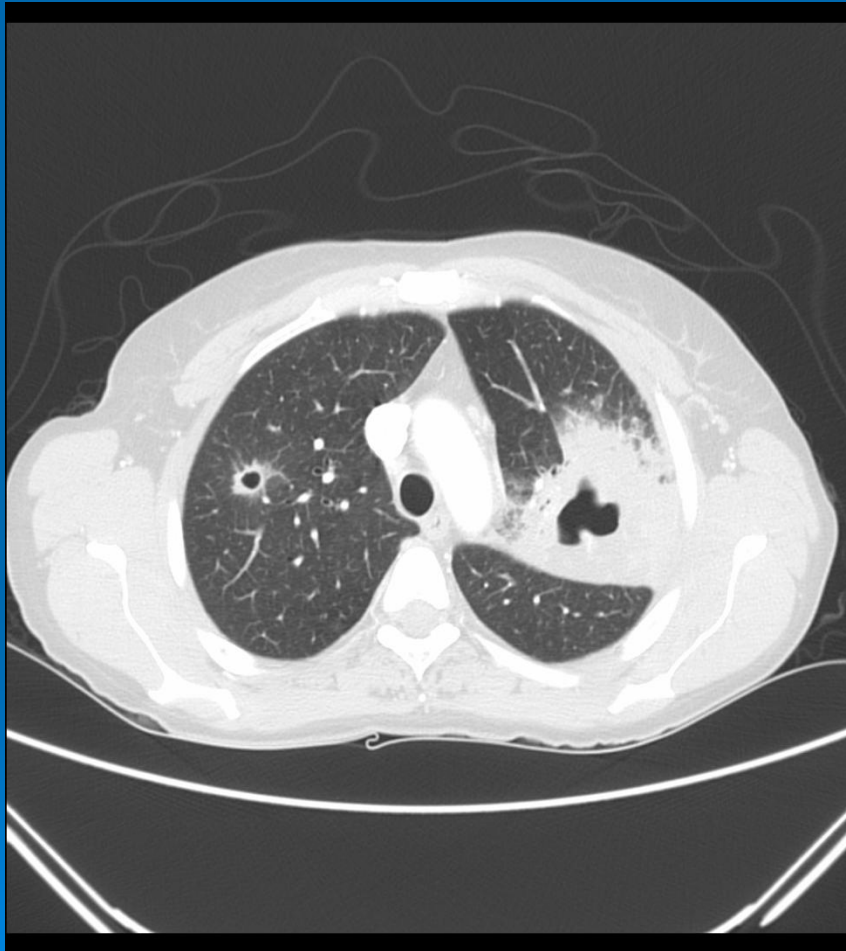
24 y/o c/o SOB



48 y/o with cough



Beware satisfaction of search



Df dx multiple pulmonary cavities

TB

Fungal disease

Necrotizing pneumonia

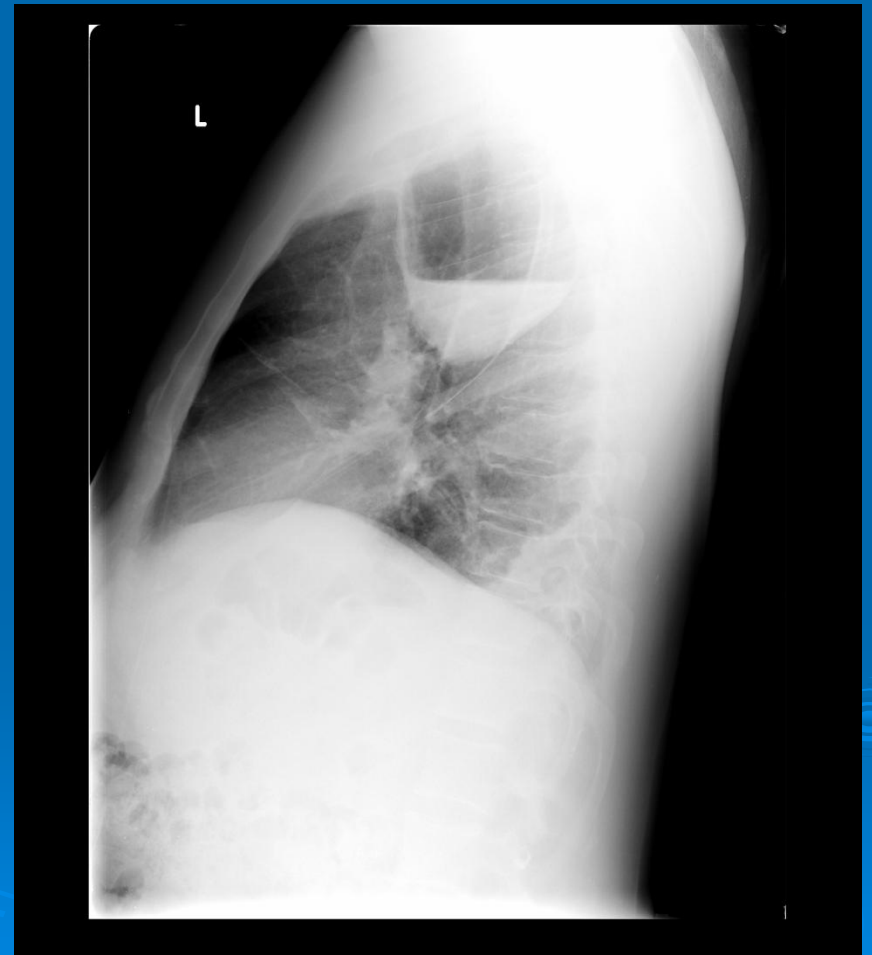
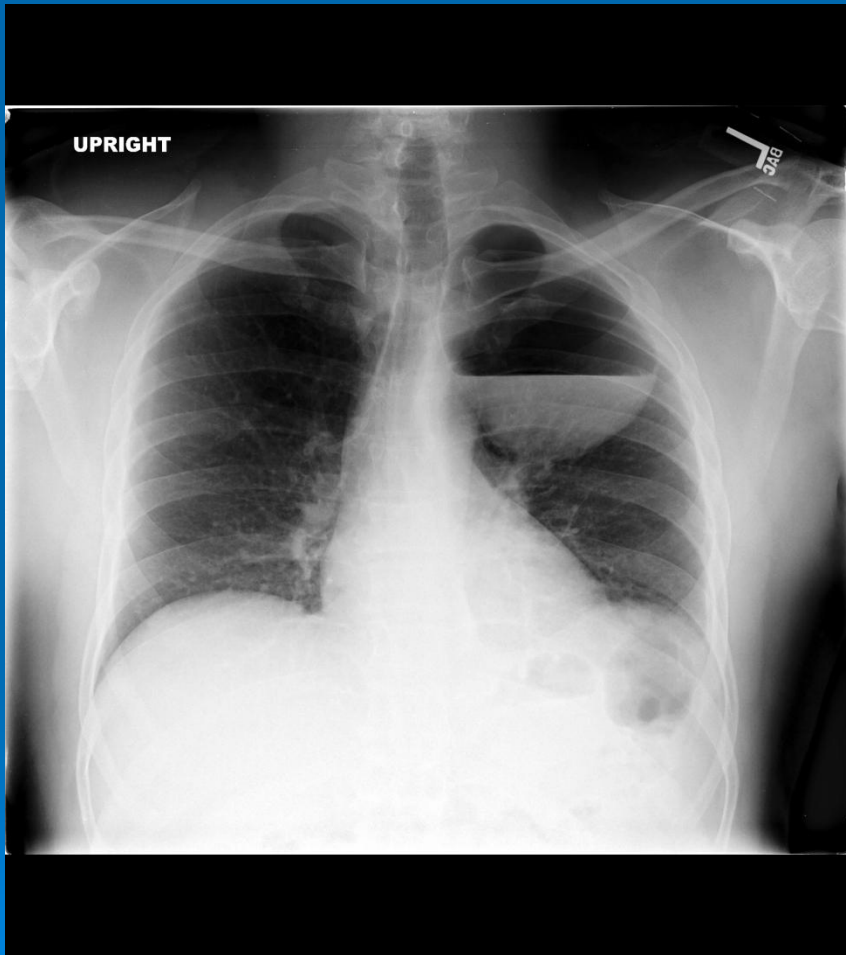
Septic emboli

Vasculitides/Collagen vascular disease

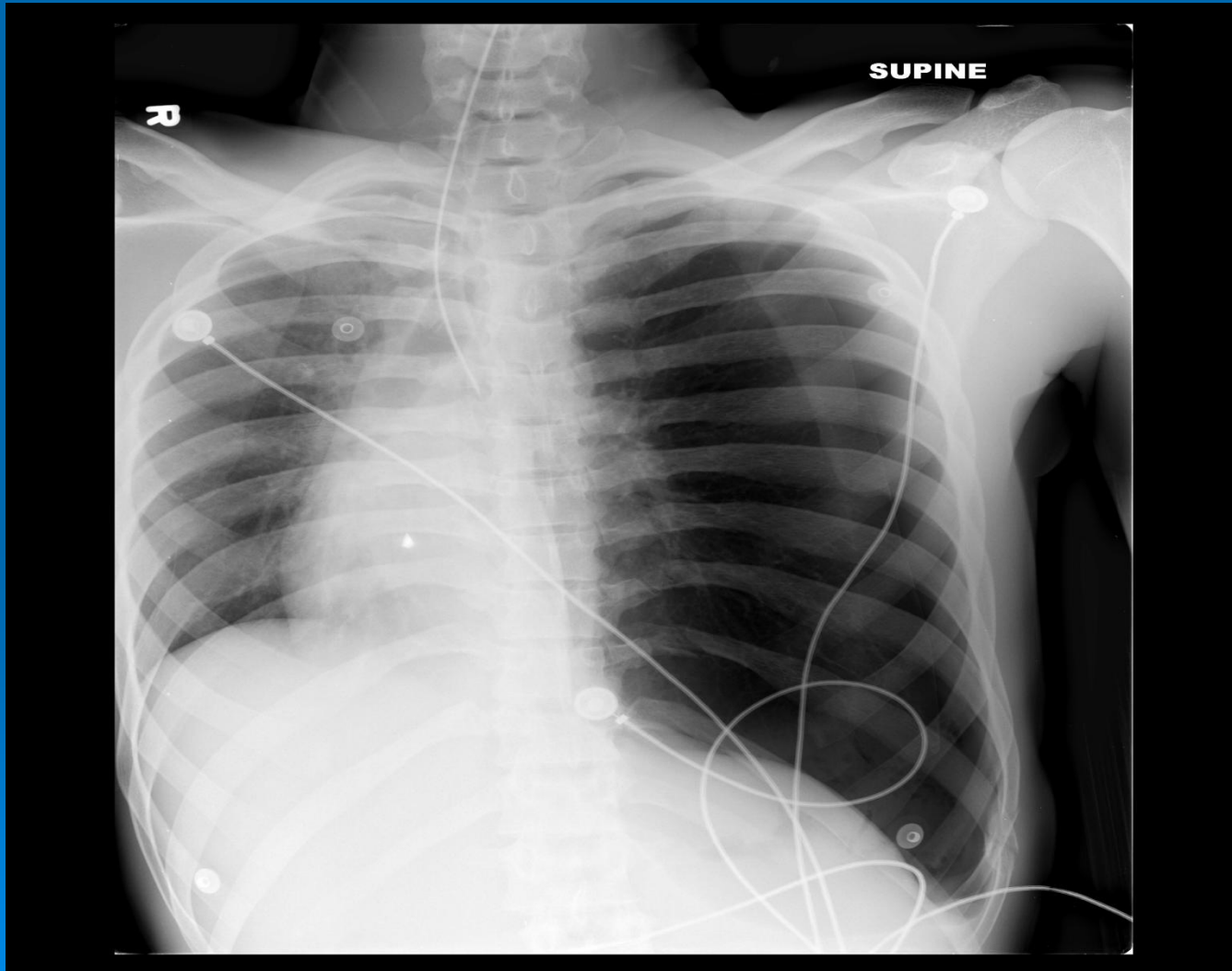
Neoplasm



50 y/o with CP



22 y/o struck by train

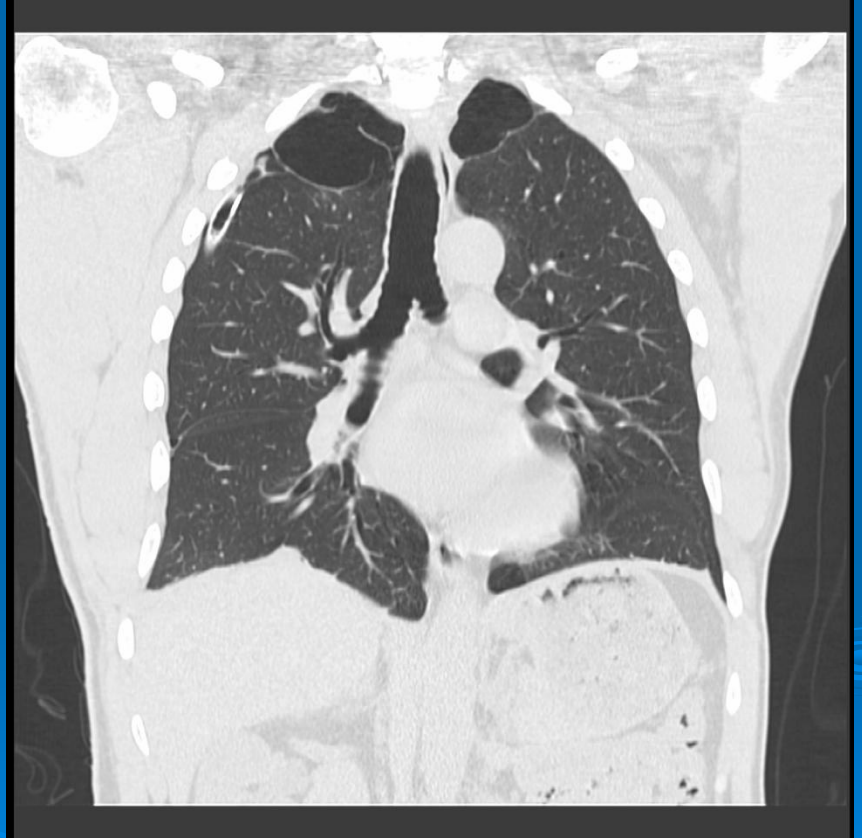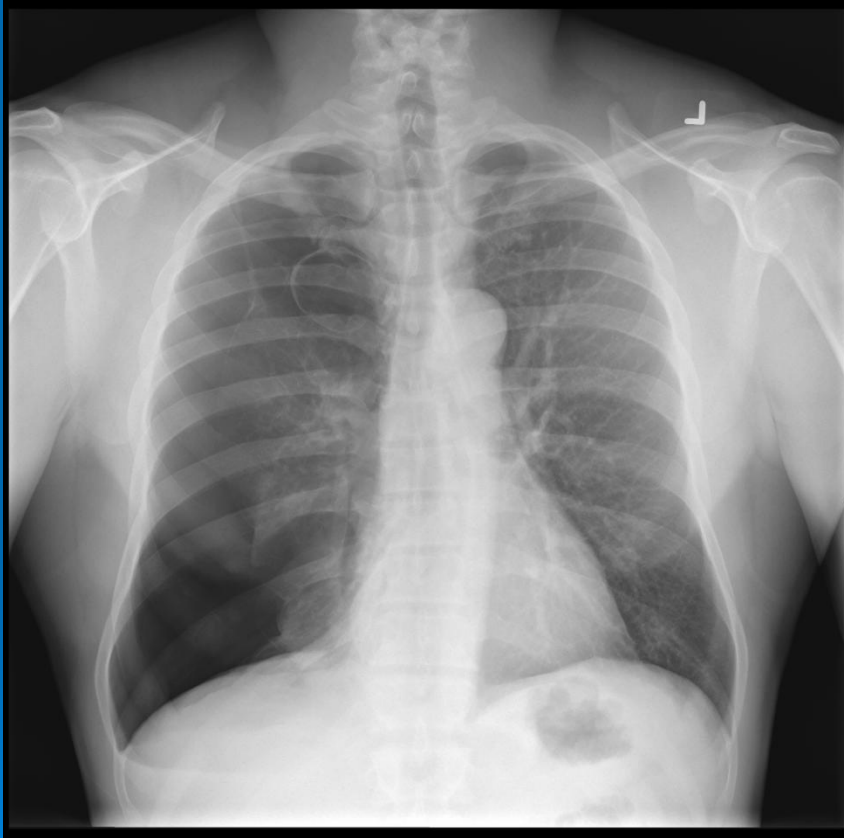


Df dx life threatening CP (courtesy of Dr. Sanders):

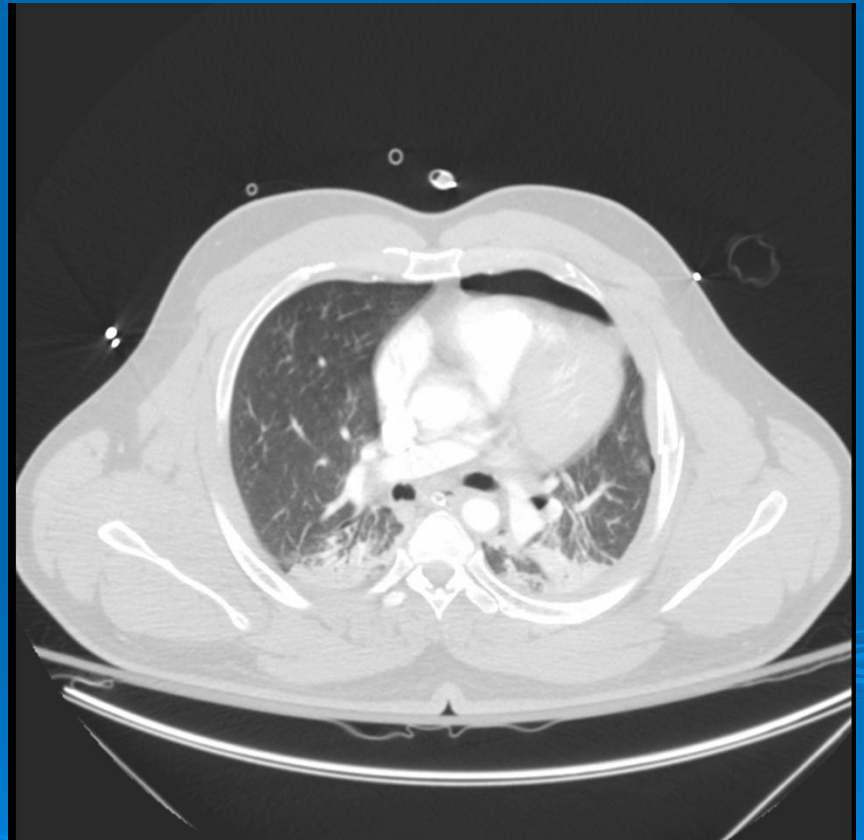
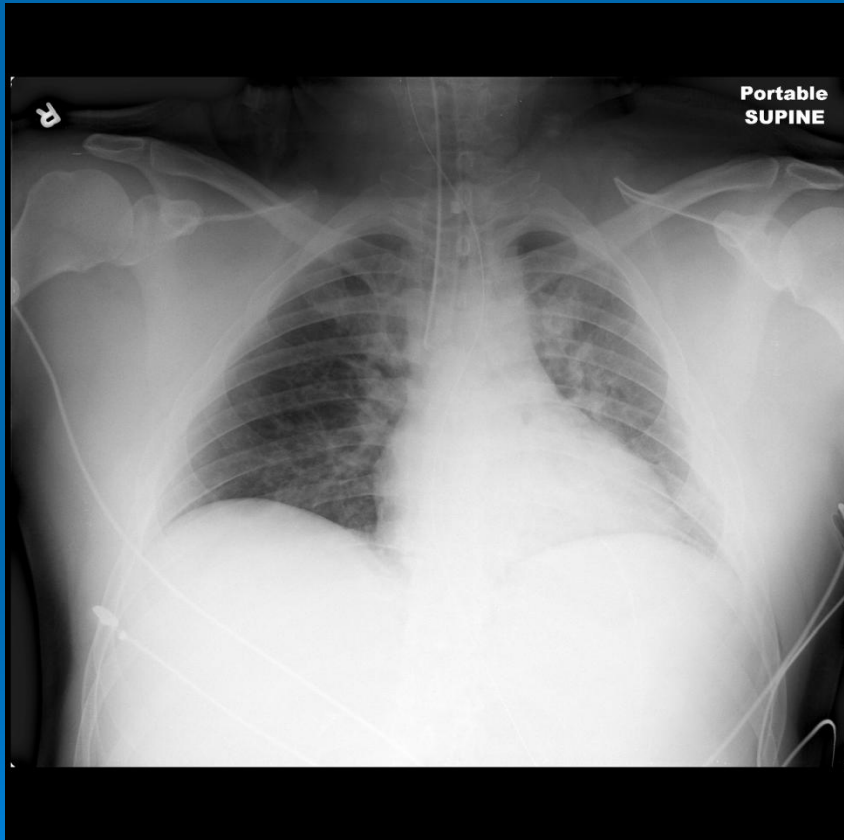
P
E
T
M
D



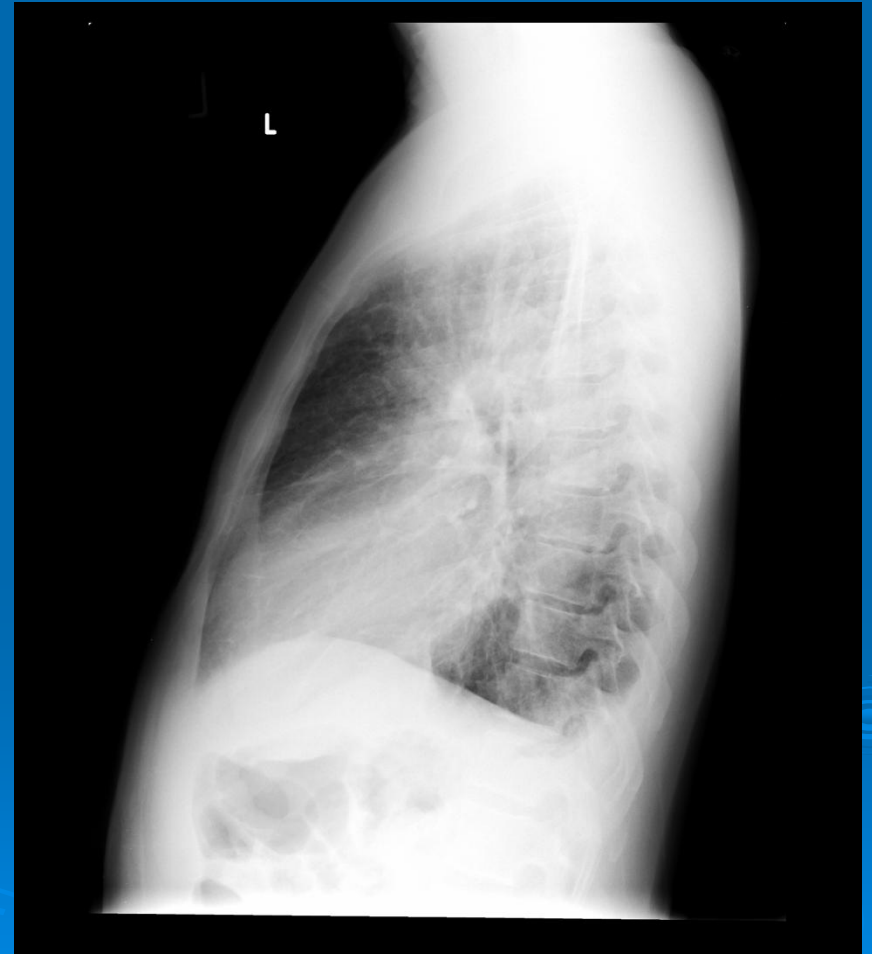
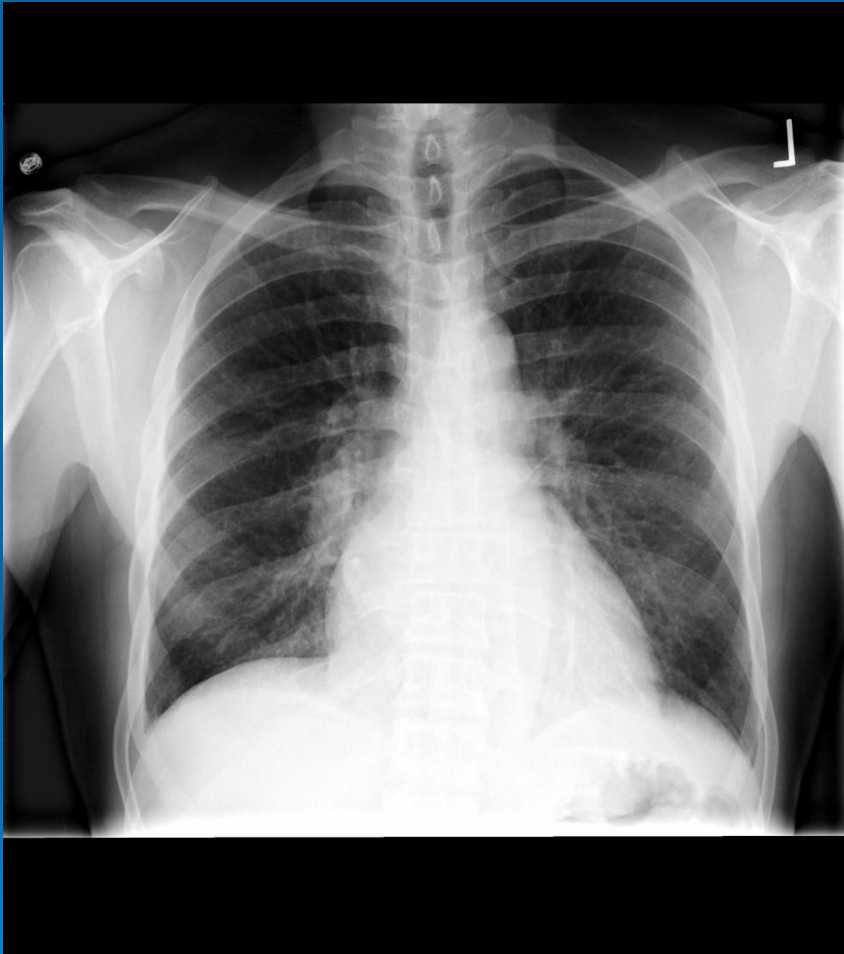45 y/o c/o CP, SOB



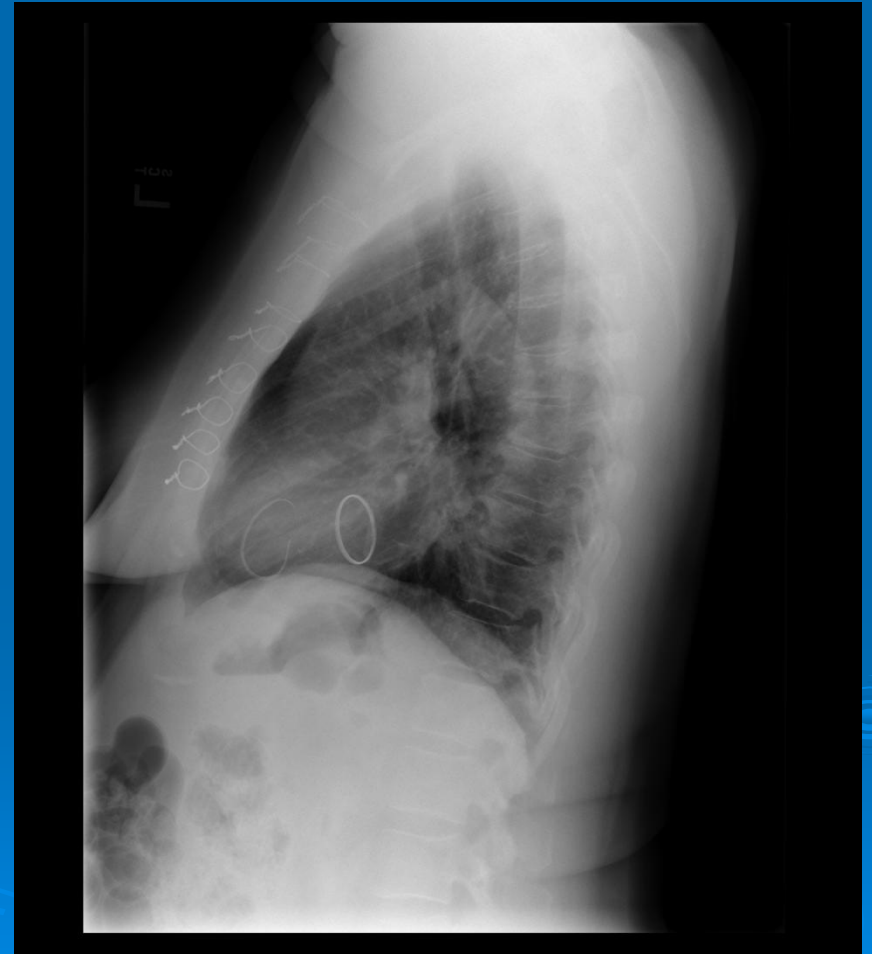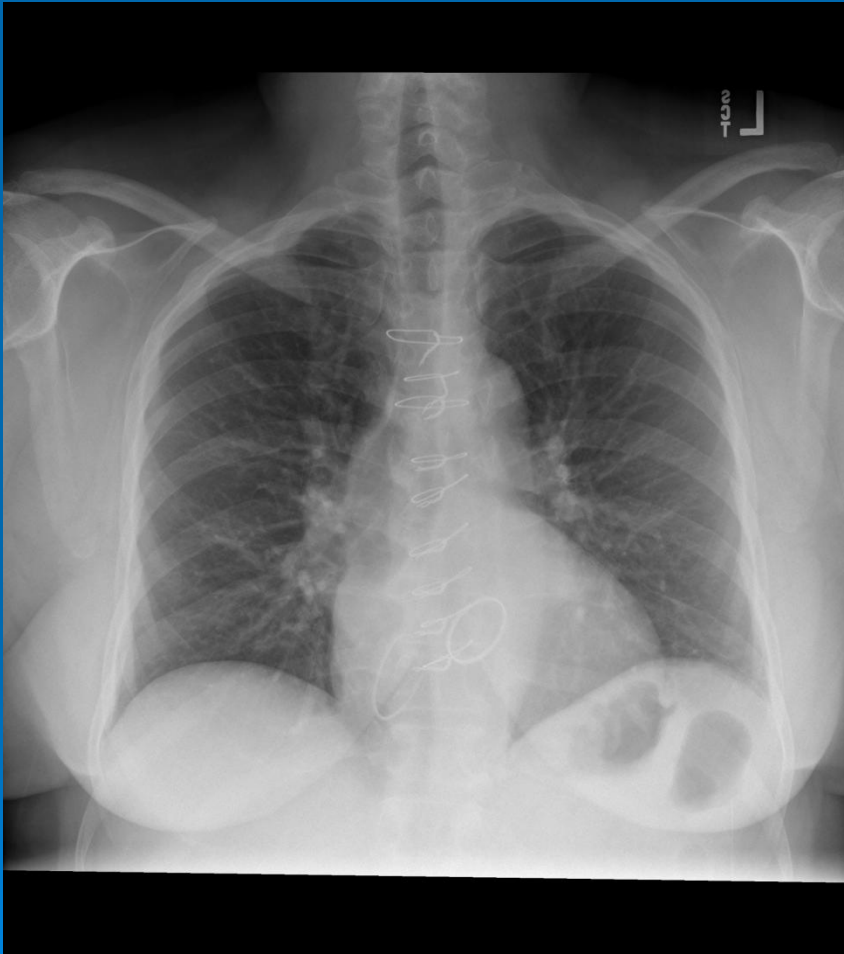
*38 y/o in MVC: ICH



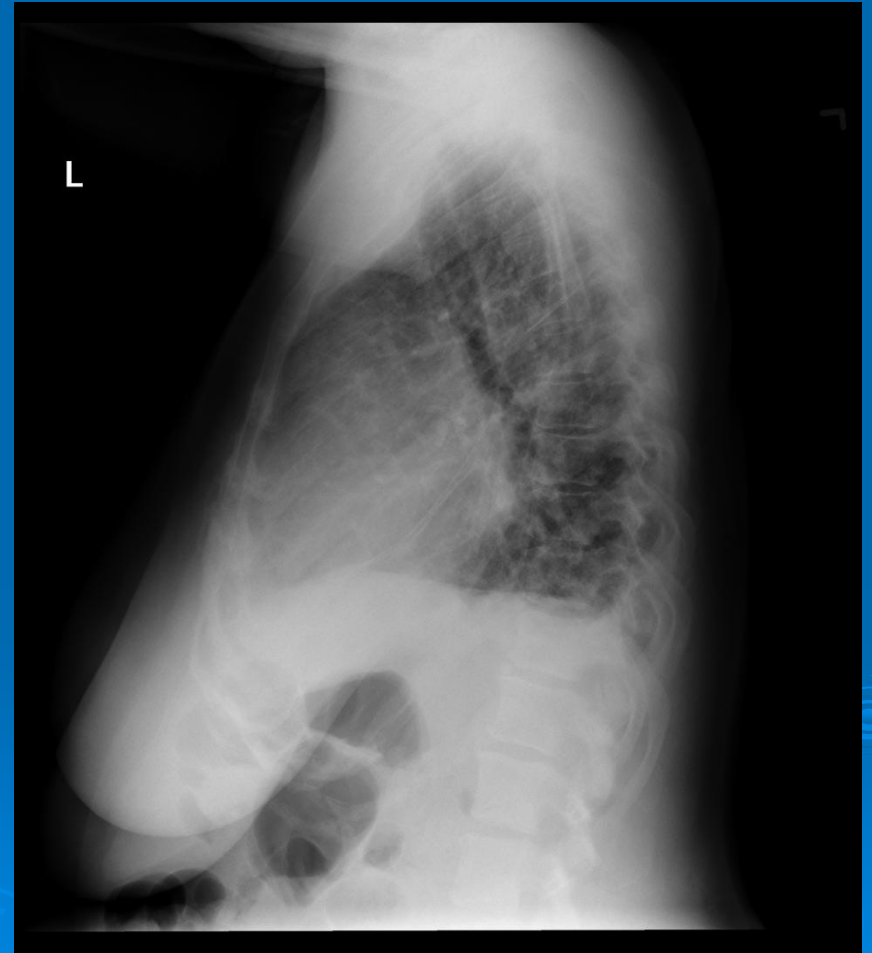
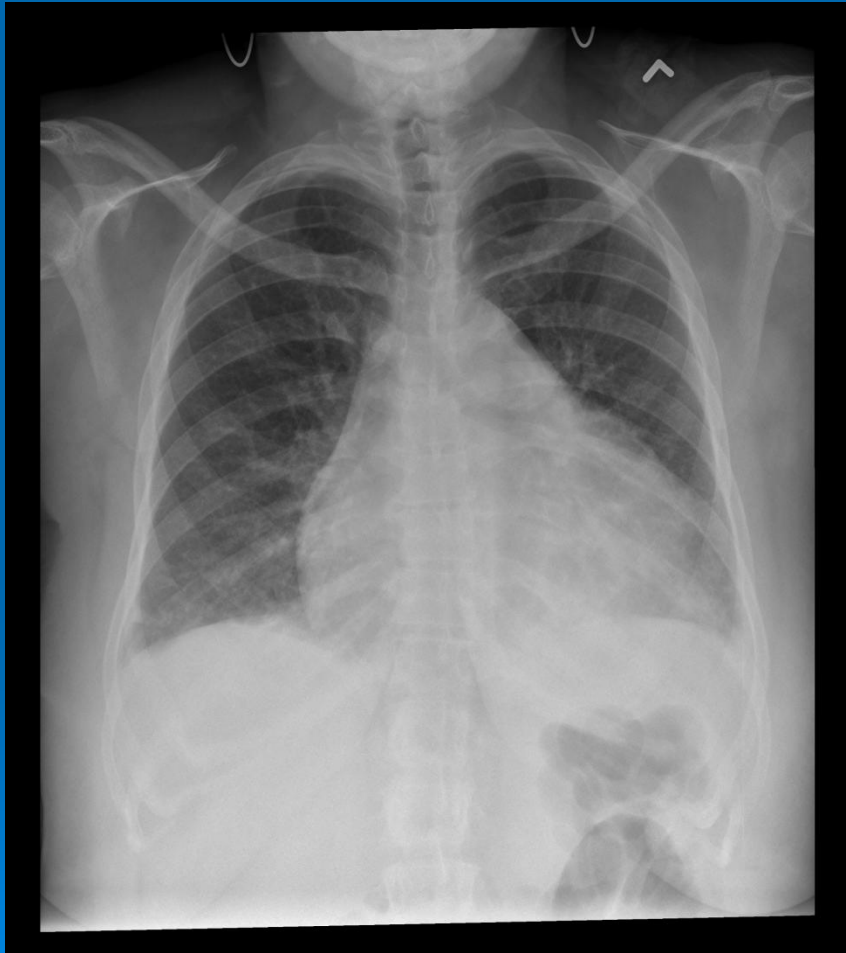
50 y/o with SOB



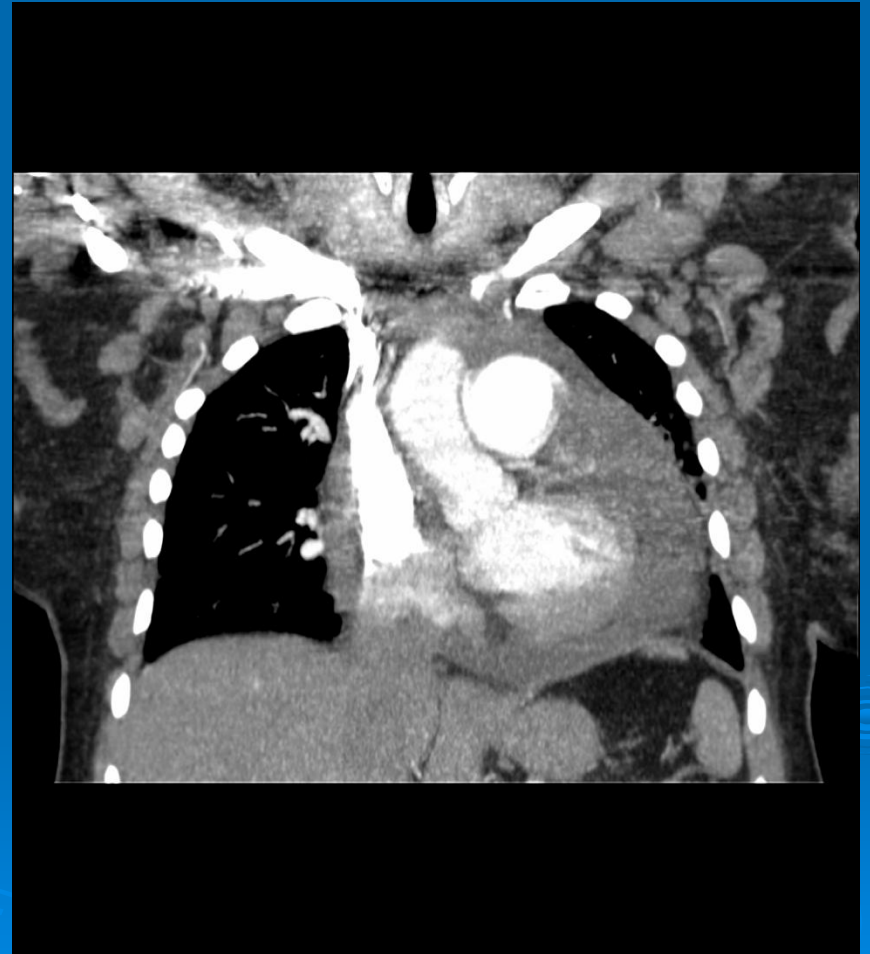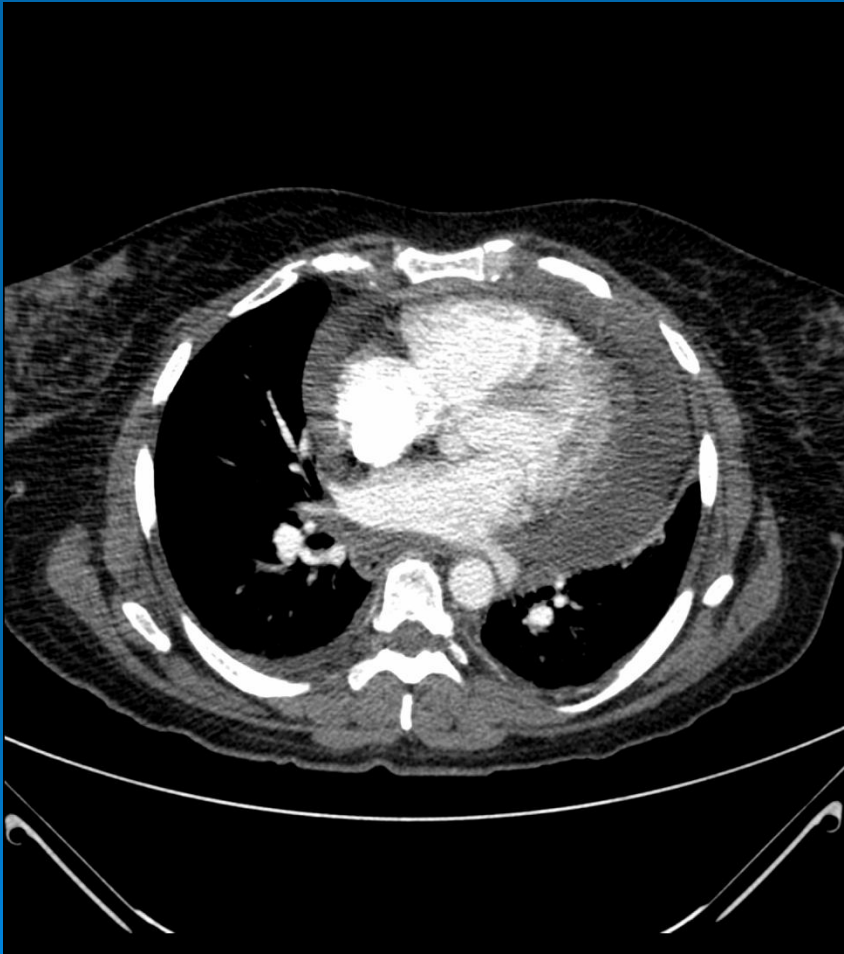
Hx rheumatic valvular disease



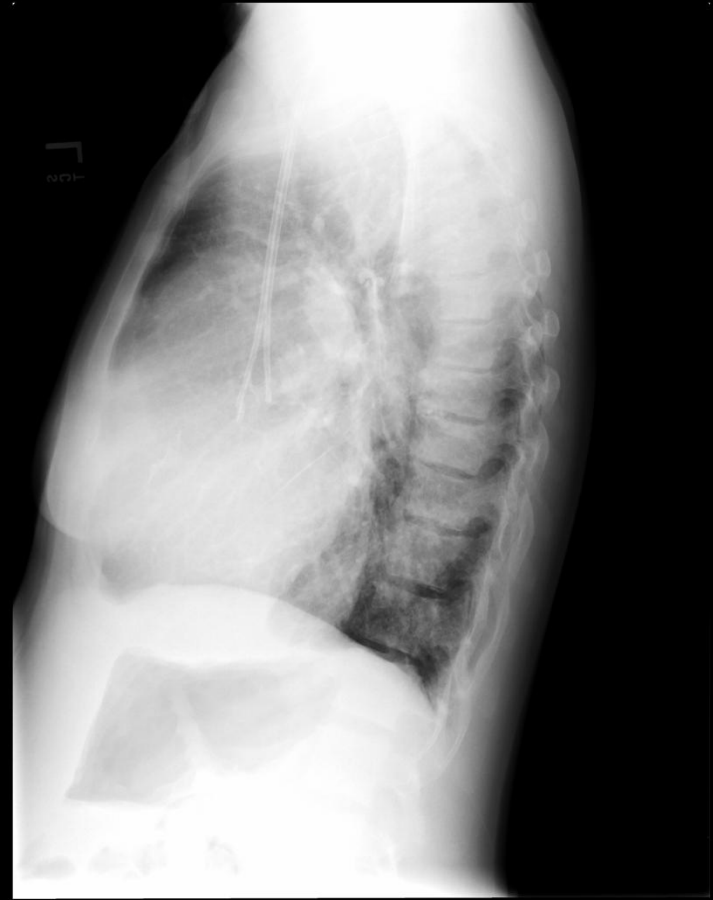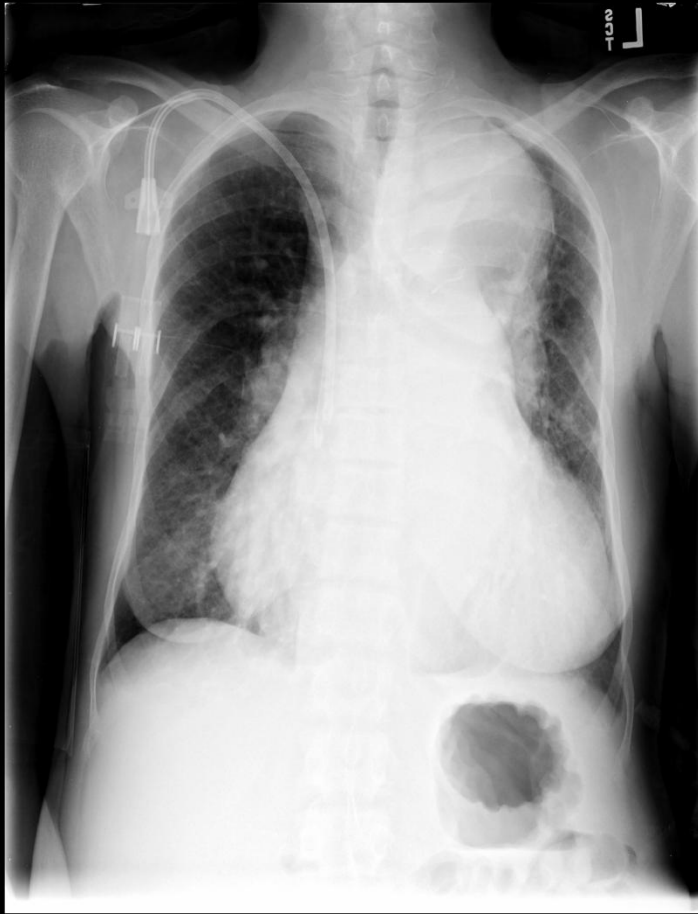54 y/o c/o CP



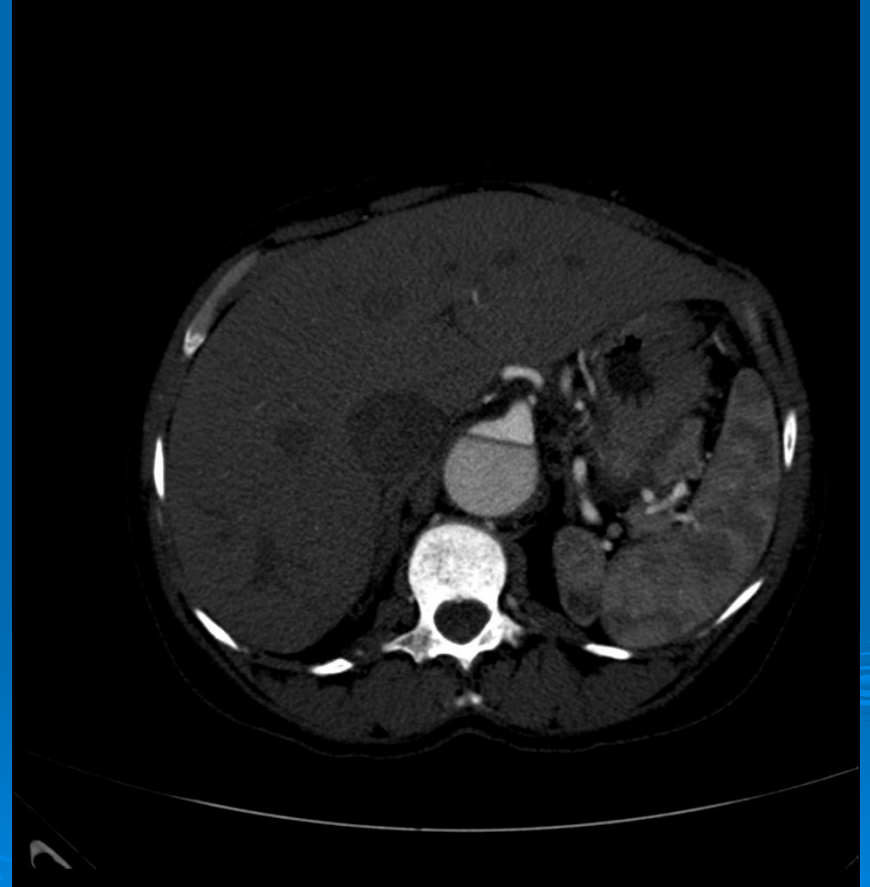
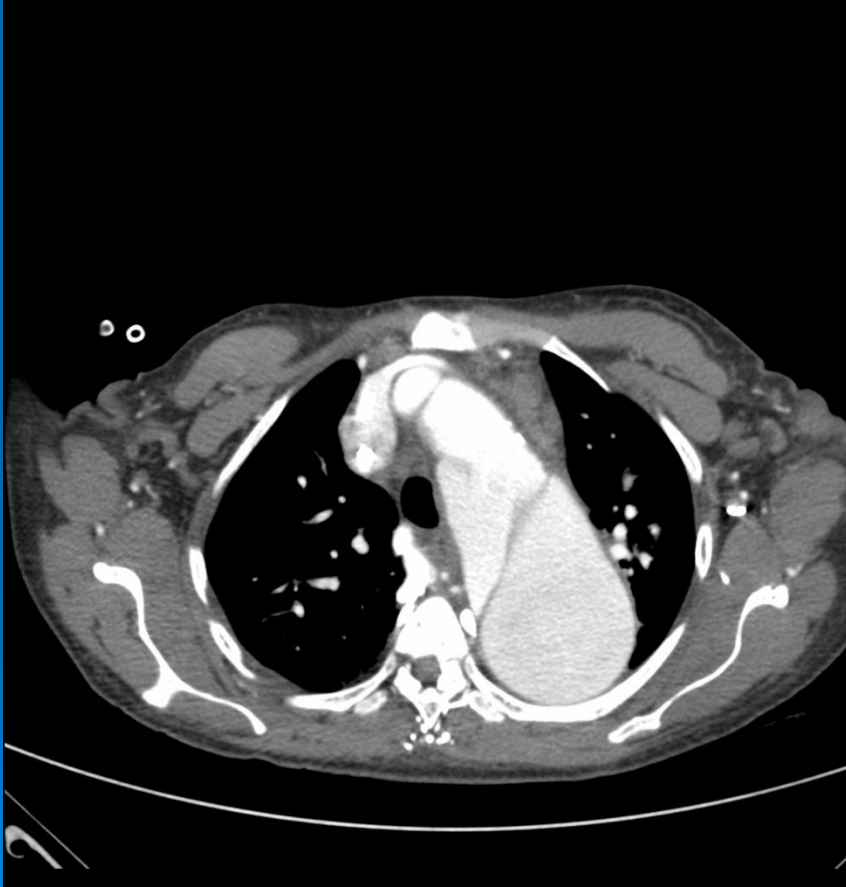
Heart v. cardiac silhouette



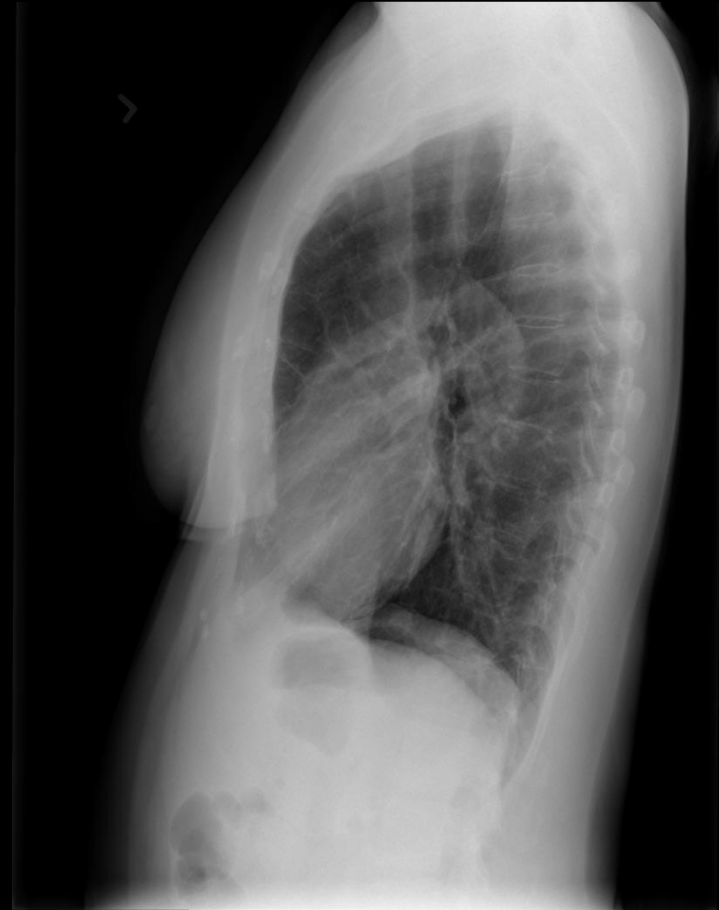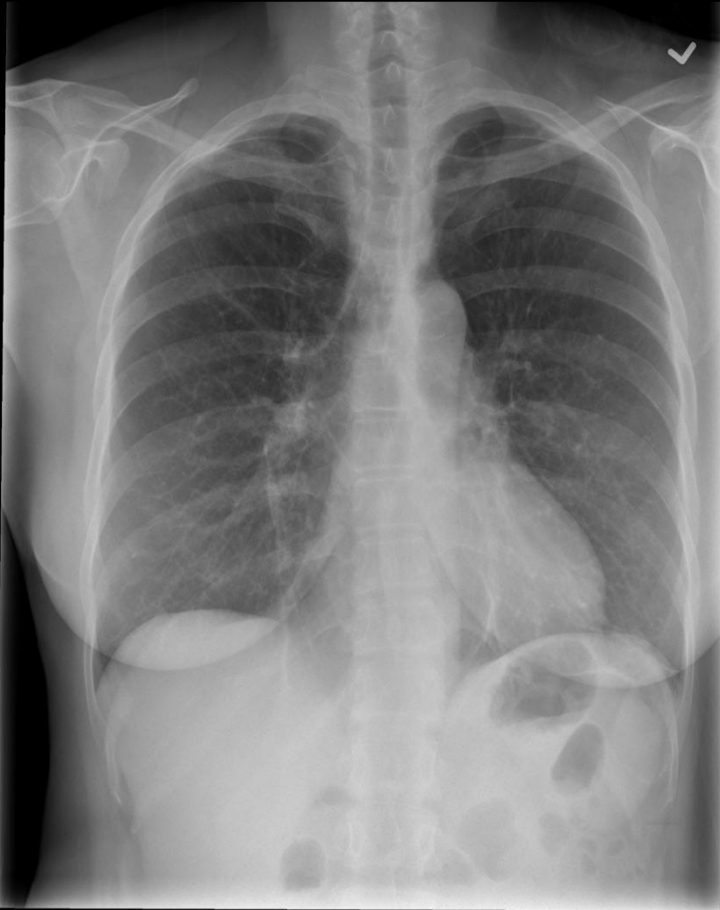
53 y/o with CP



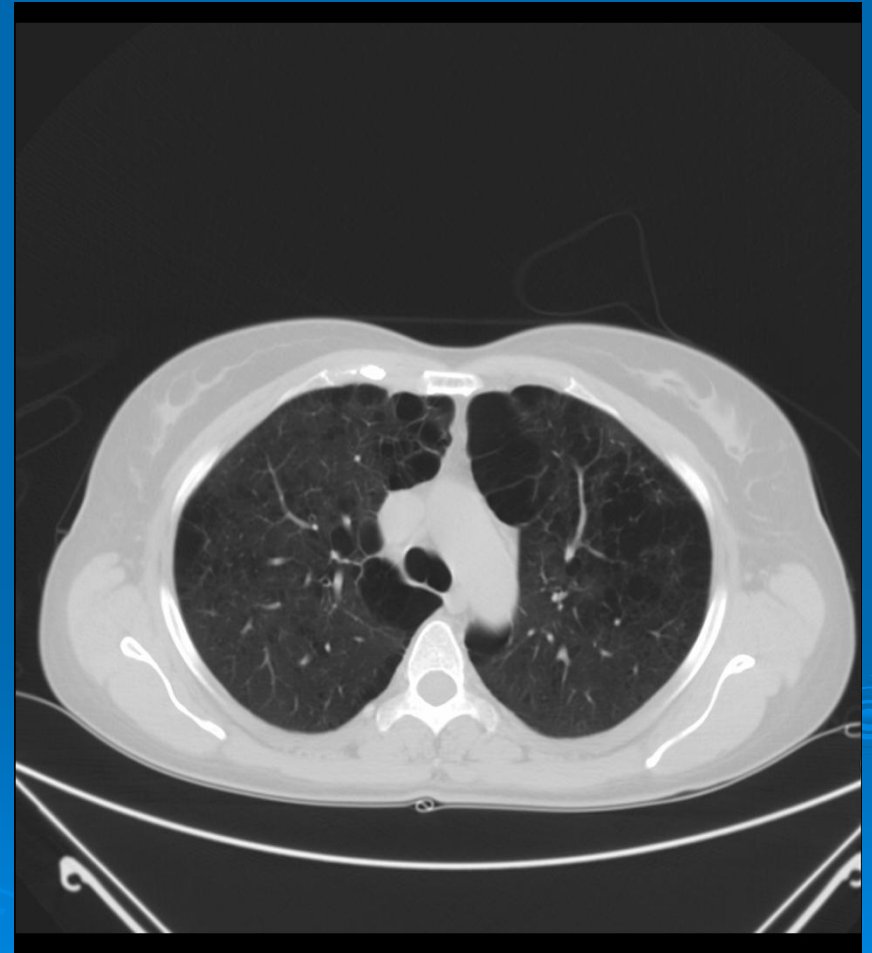
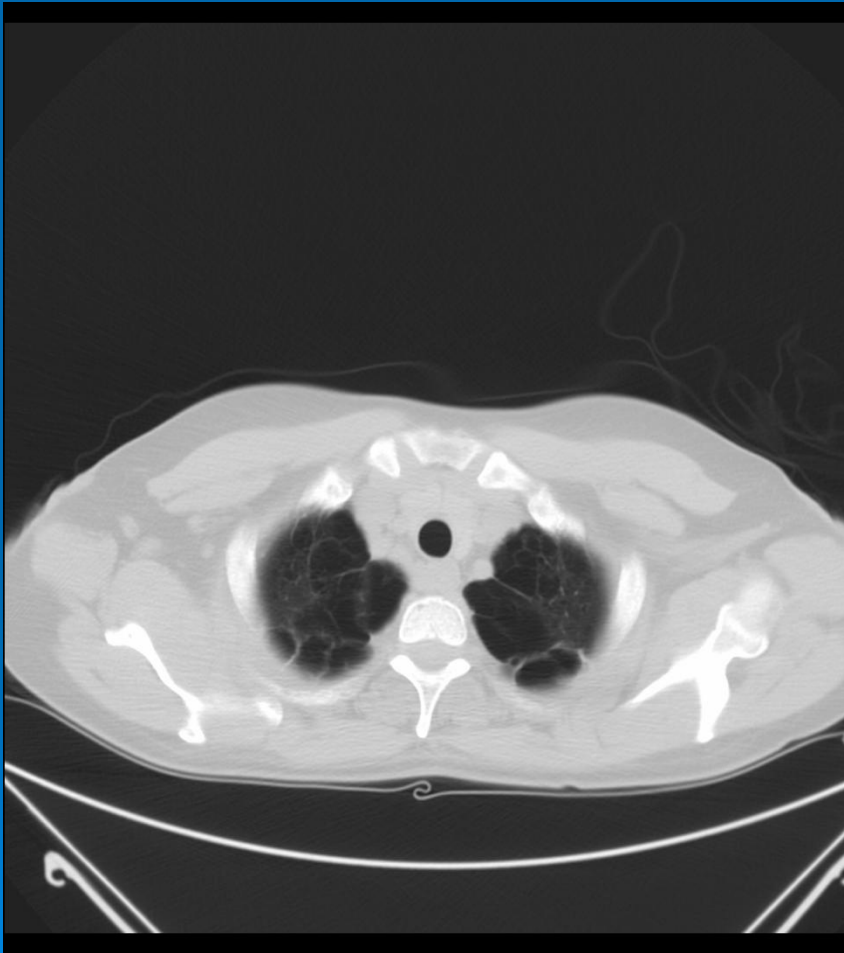
petmD



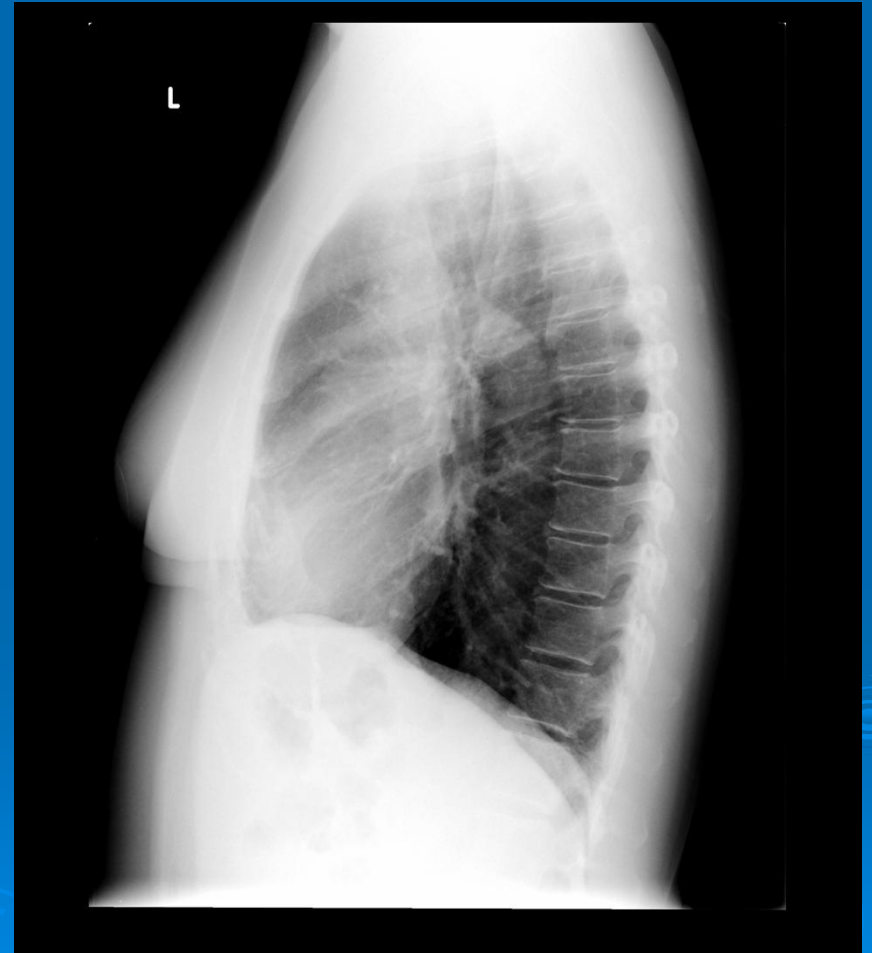
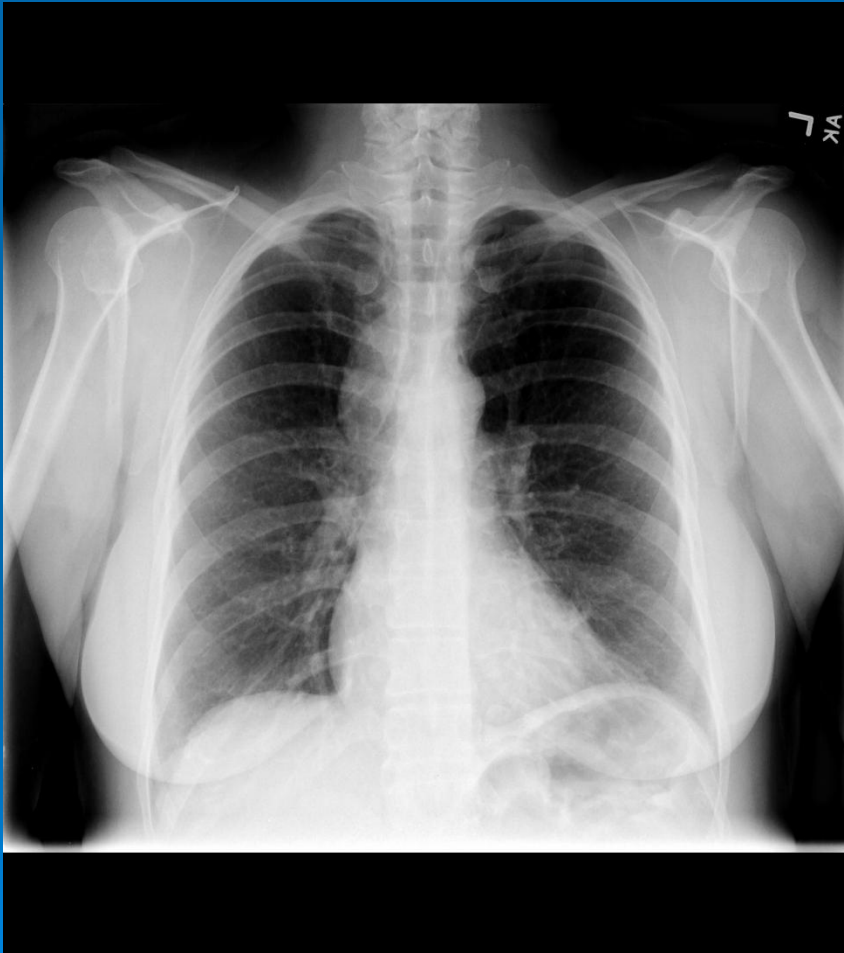
48 y/o smoker



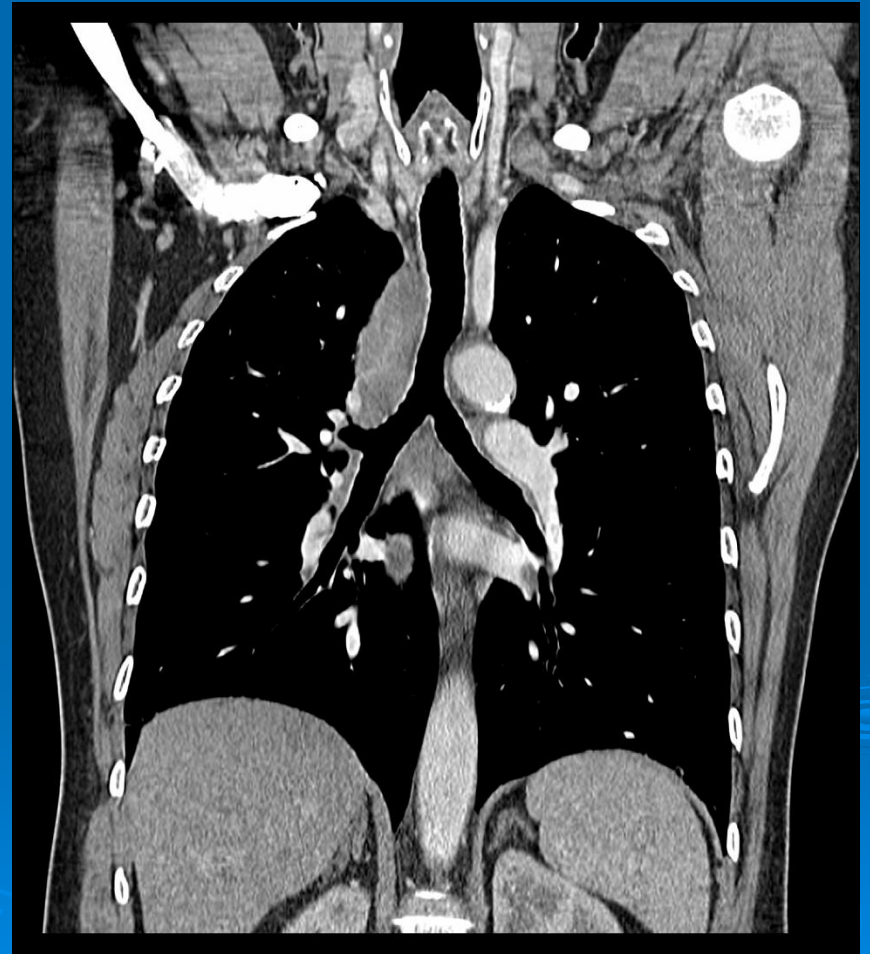
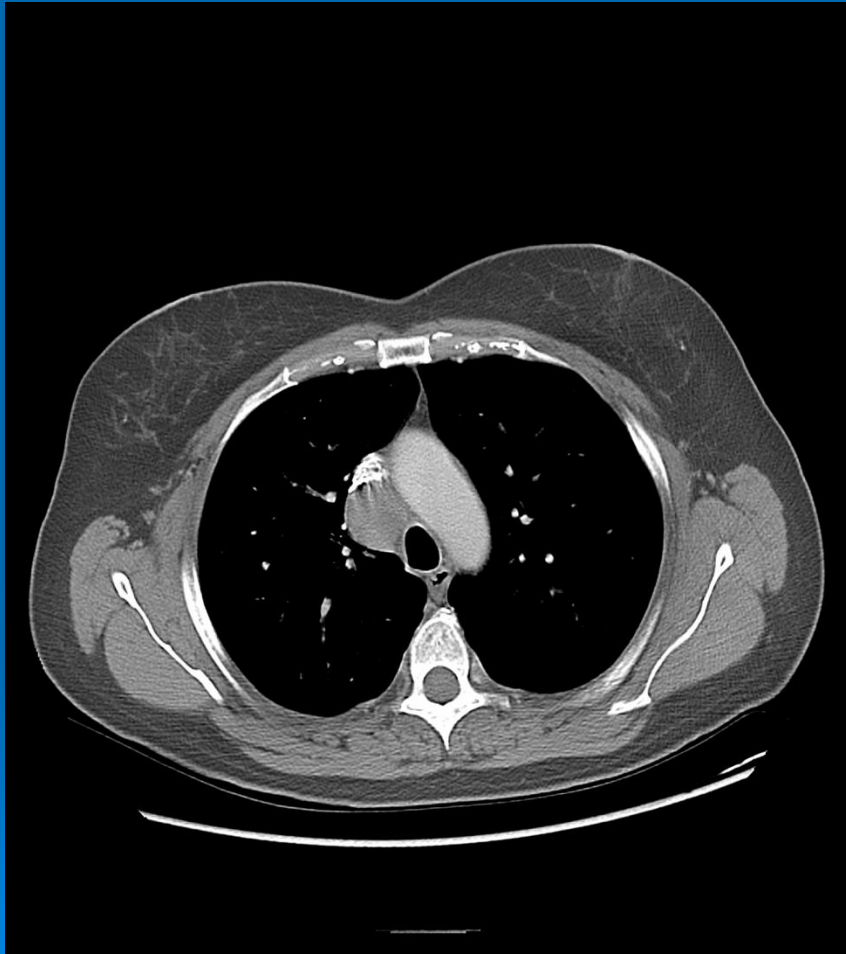
What is COPD?



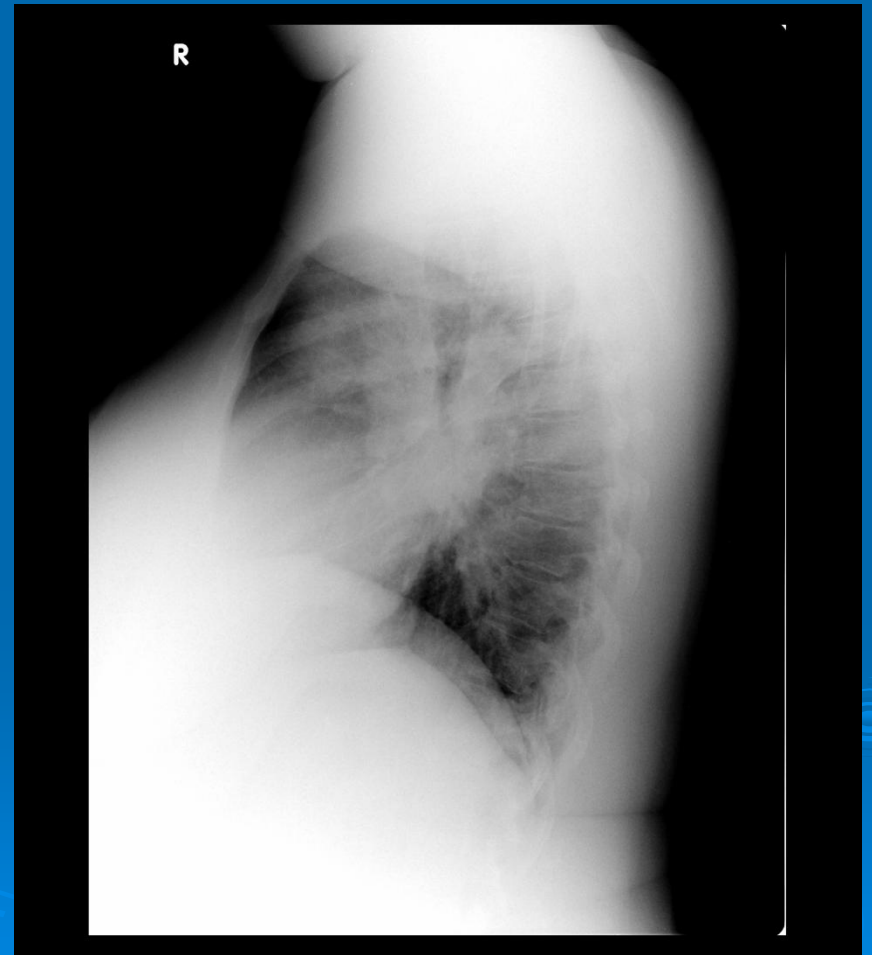
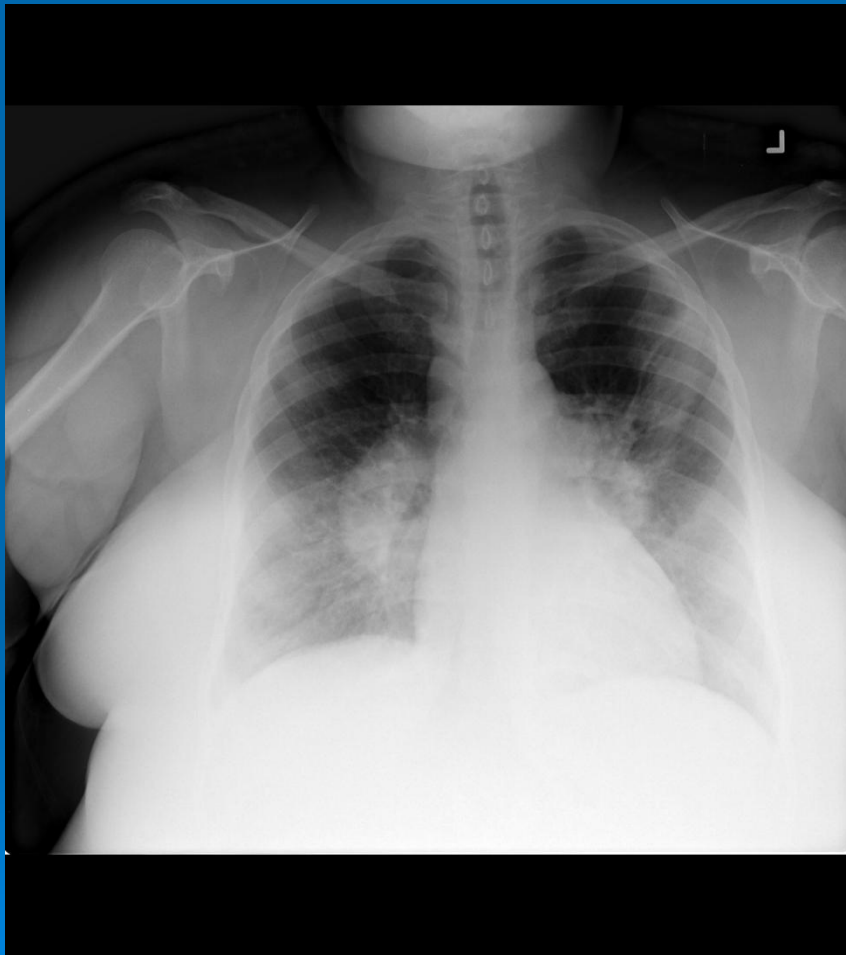
49 y/o c/o SOB



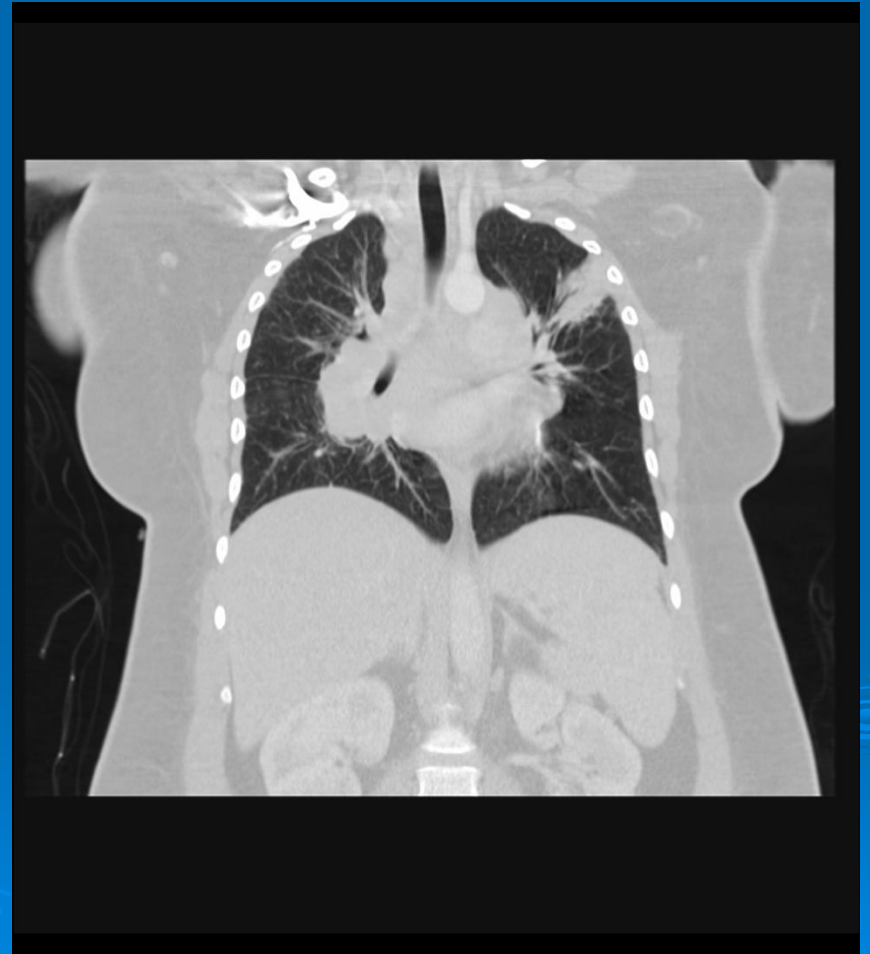
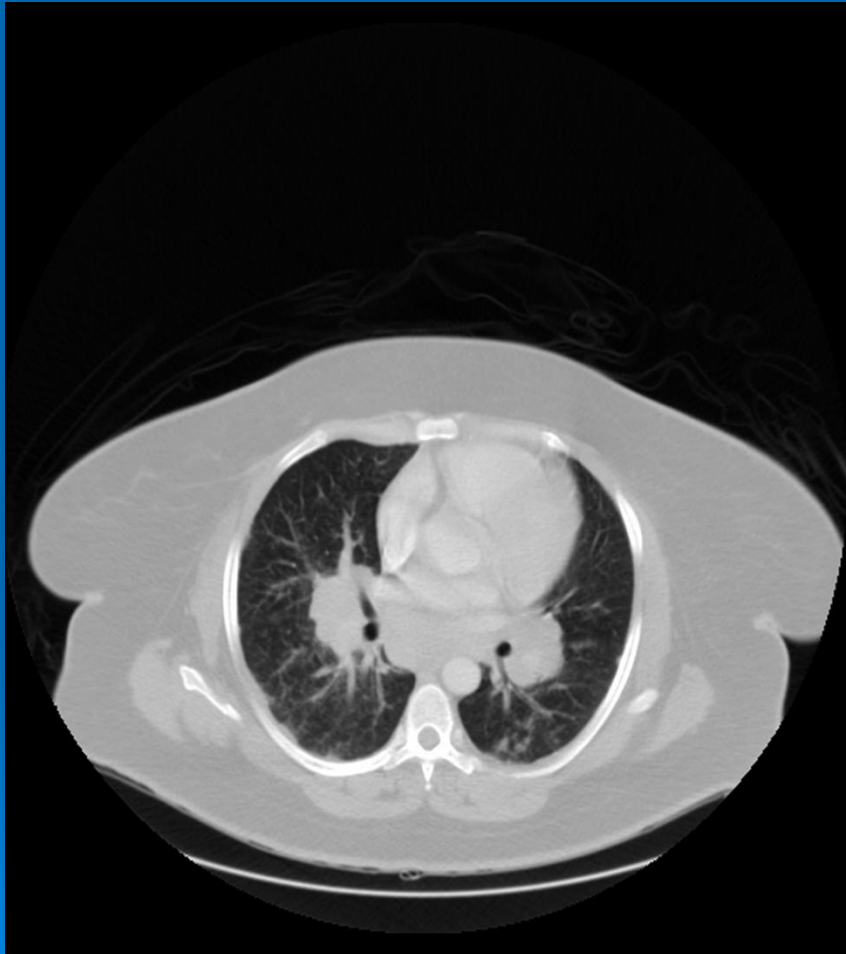
No sx myasthenia gravis



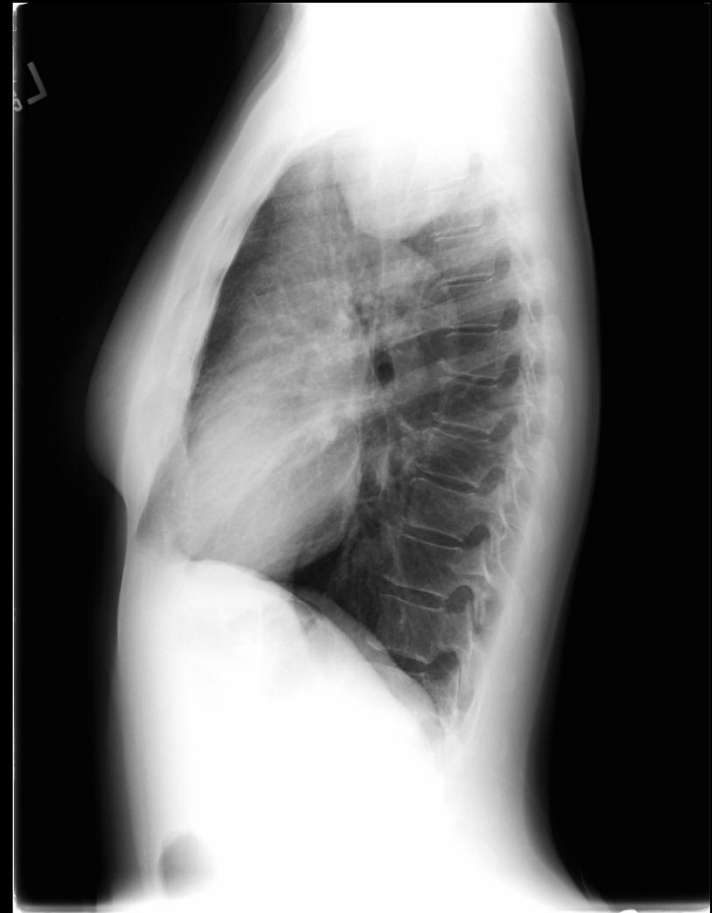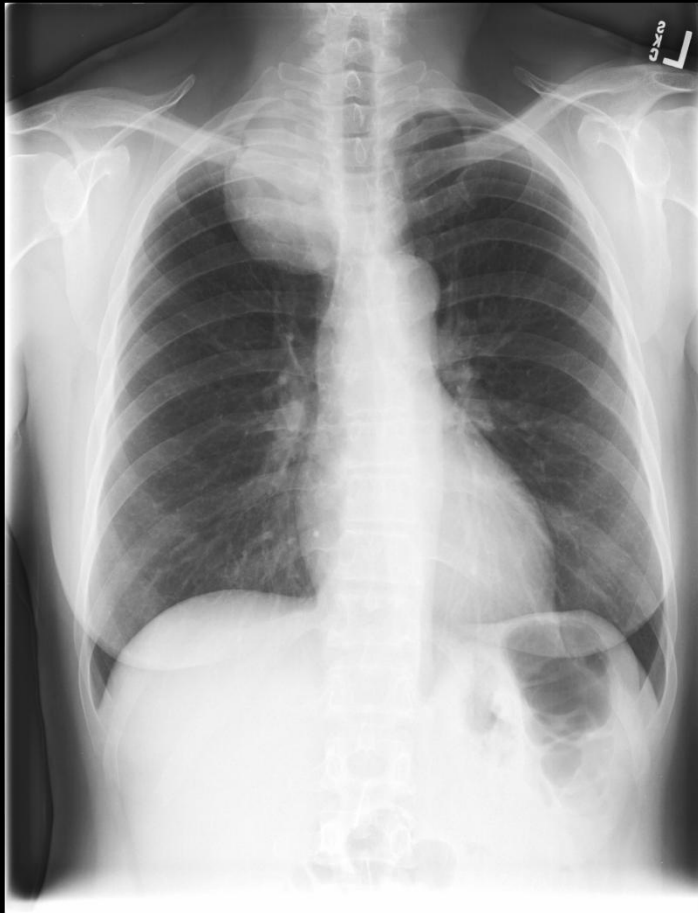34 y/o with c/o SOB



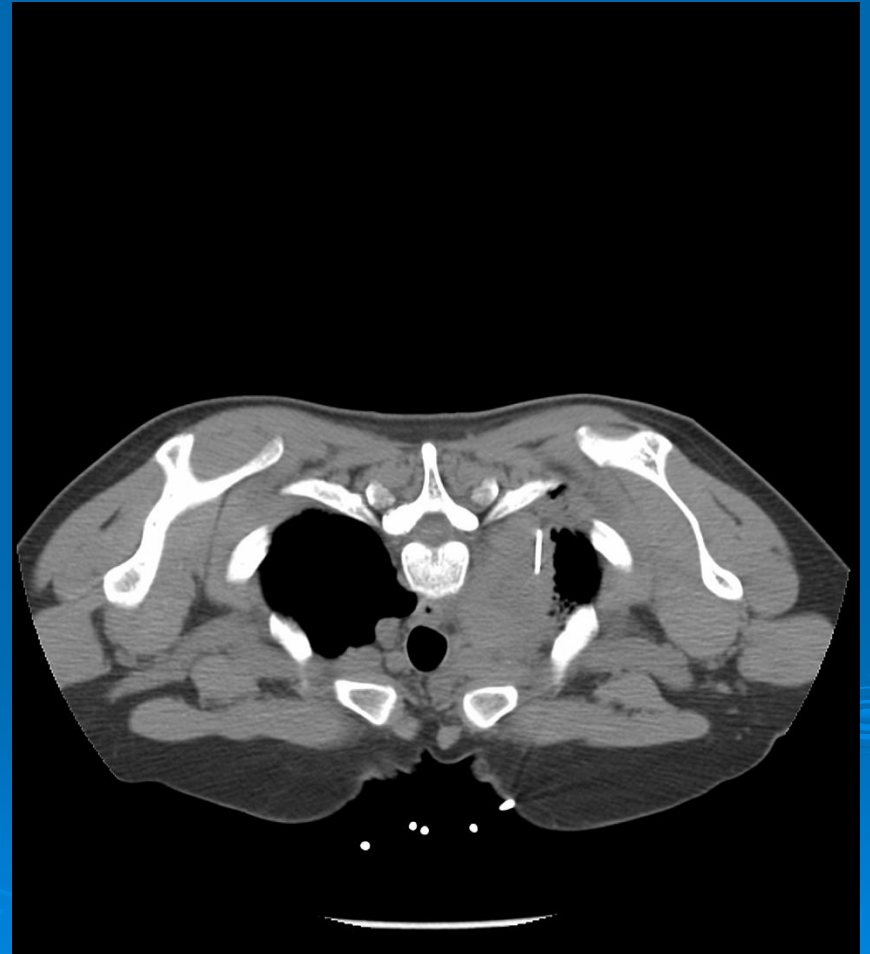
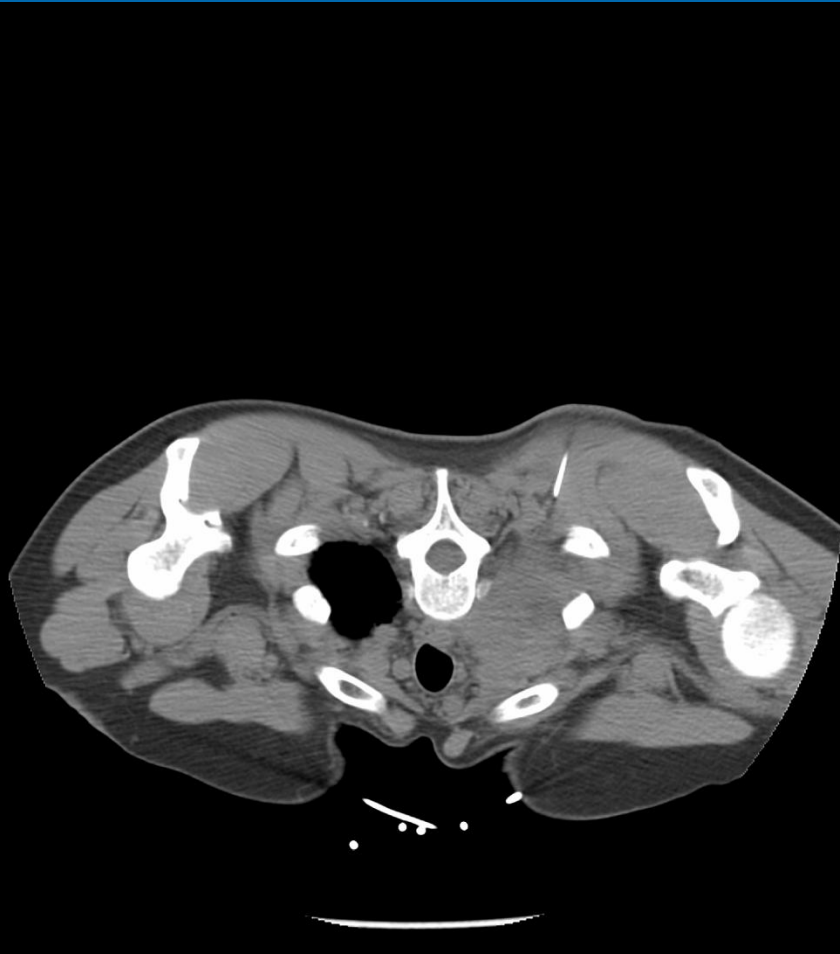Stage II



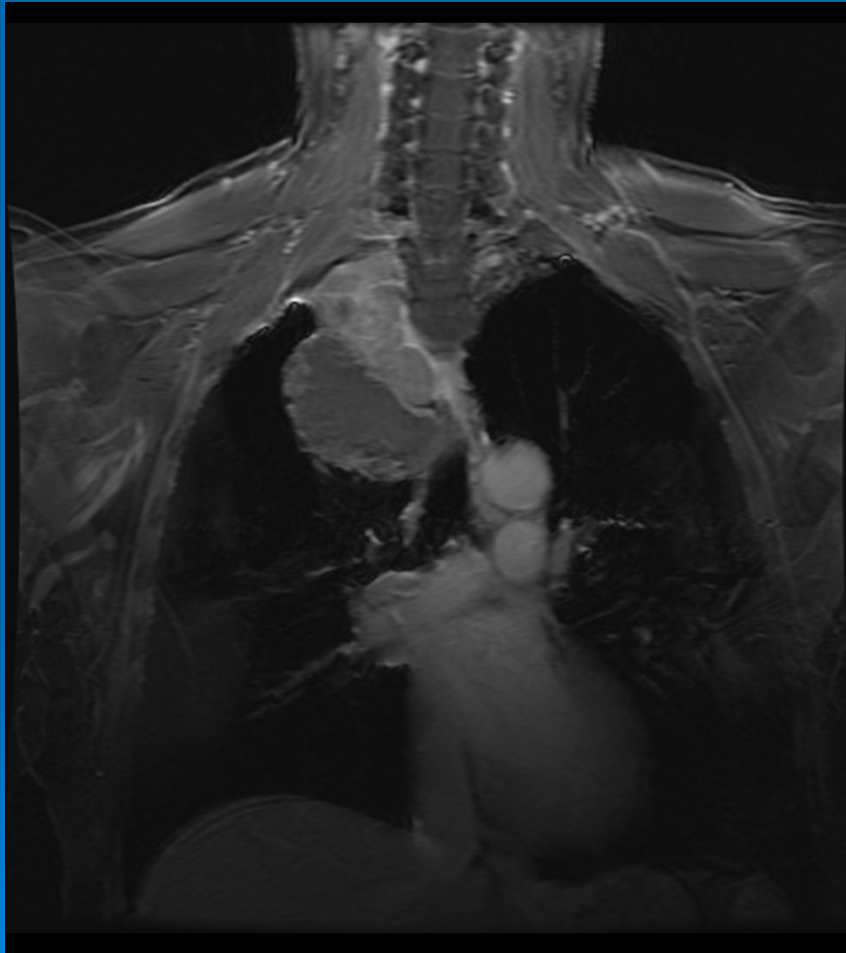
49 y/o with ptosis & RUE pain



Next?



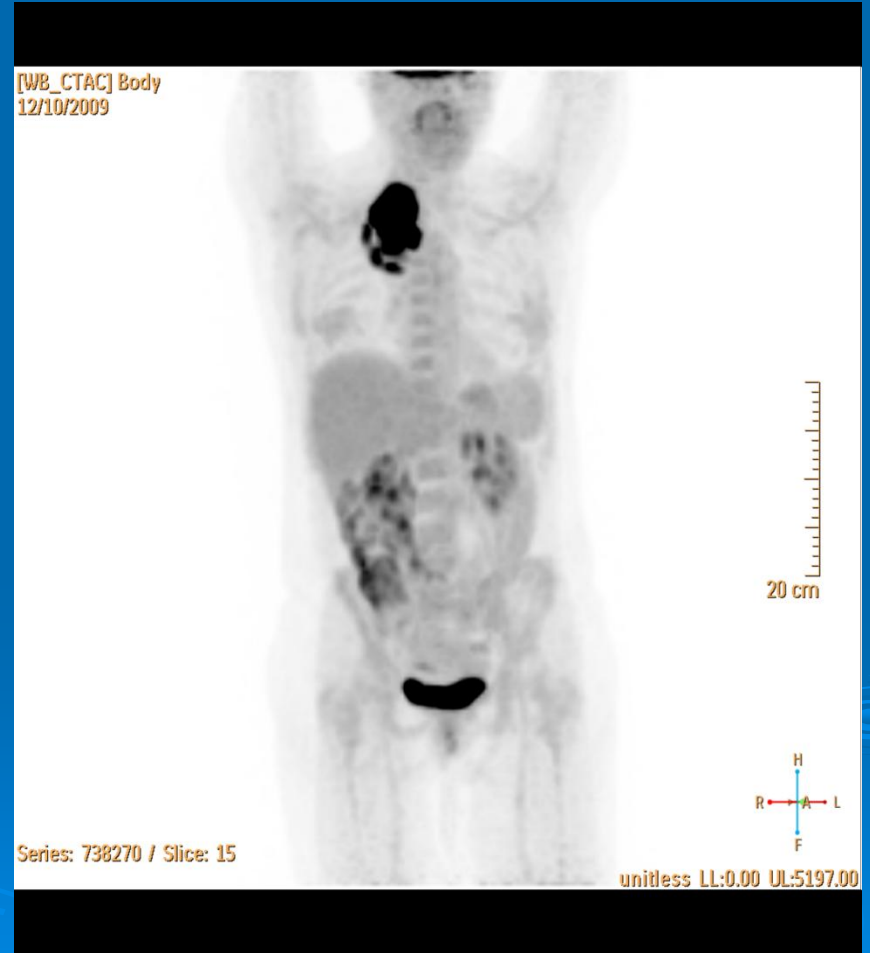
Then?



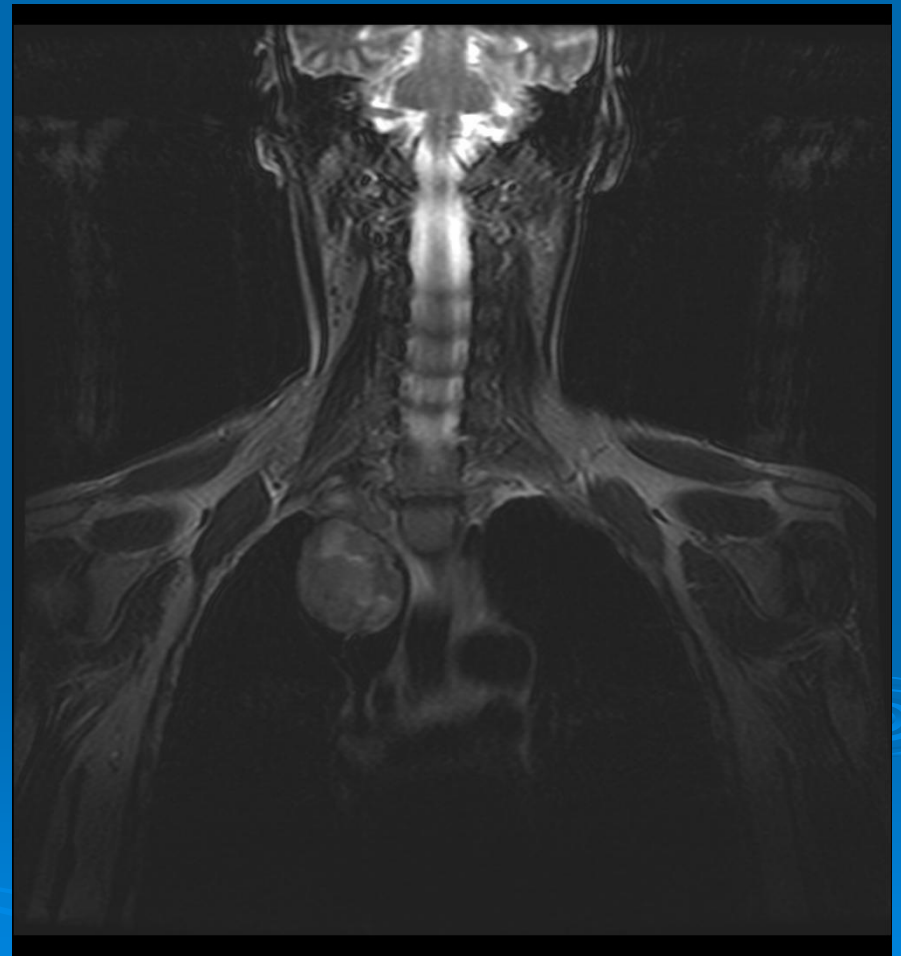
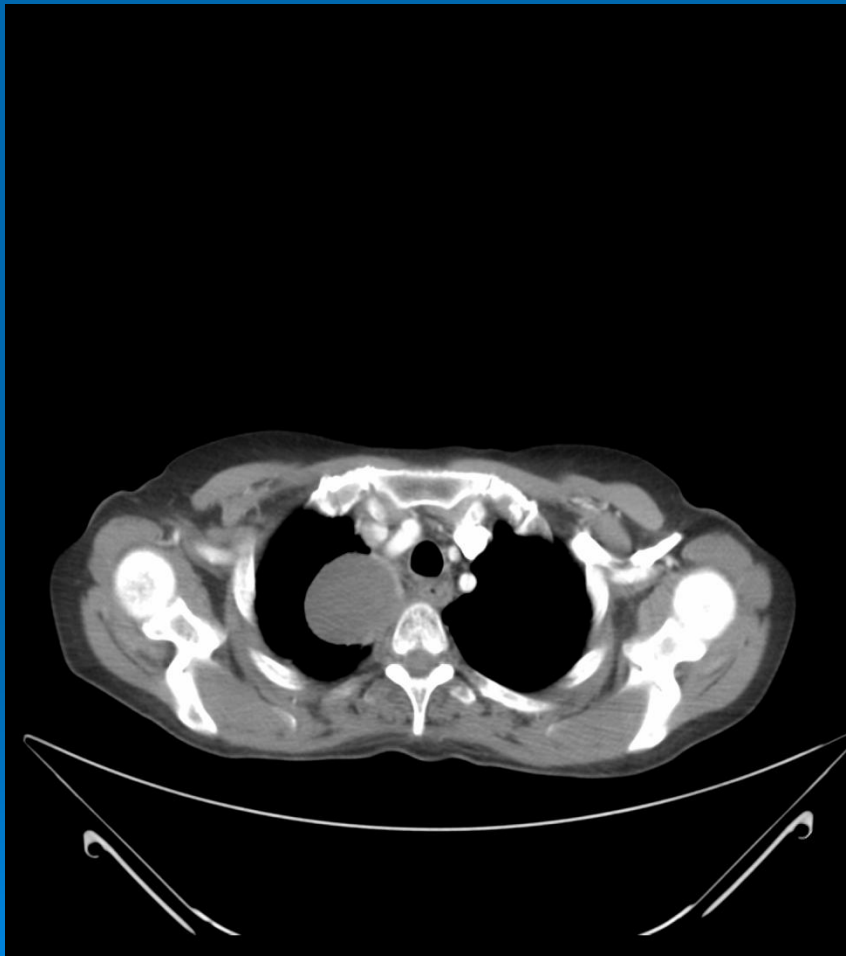
[WB_CTAC] Body
12/10/2009

Series: 738270 / Slice: 15

unitless LL:0.00 UL:5197.00



s/p chemo and rad tx

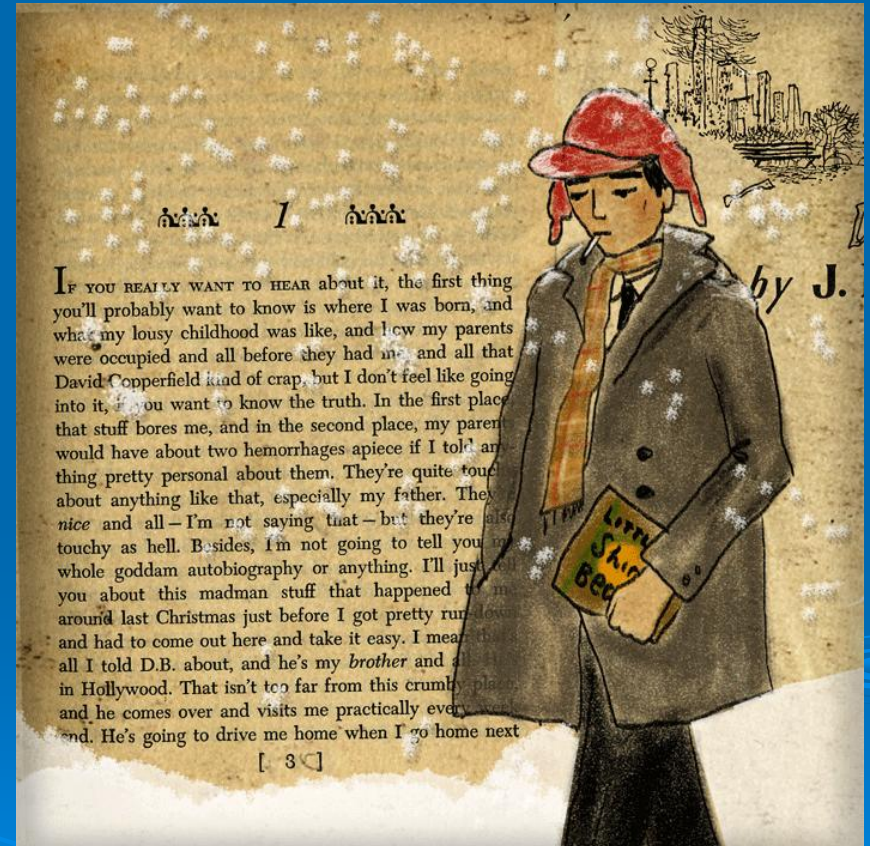


*Possible test question:

With reference to the non-medical literature, a radiologist should emulate:

- a. Miss Havisham
- b. Scout Finch
- c. Sherlock Holmes
- d. Holden Caulfield
- e. c & d

Notice the hats.



~~~~~ I ~~~~~

IF YOU REALLY WANT TO HEAR about it, the first thing you'll probably want to know is where I was born, and what my lousy childhood was like, and how my parents were occupied and all before they had me, and all that David Copperfield kind of crap, but I don't feel like going into it, because you want to know the truth. In the first place, that stuff bores me, and in the second place, my parents would have about two hemorrhages apiece if I told anything pretty personal about them. They're quite touchy about anything like that, especially my father. They're nice and all—I'm not saying that—but they're also touchy as hell. Besides, I'm not going to tell you my whole goddam autobiography or anything. I'll just tell you about this madman stuff that happened to me around last Christmas just before I got pretty run-down and had to come out here and take it easy. I mean, that's all I told D.B. about, and he's my *brother* and all that in Hollywood. That isn't too far from this crummy place, and he comes over and visits me practically every weekend. He's going to drive me home when I go home next

by J.